

# Long-Term Efficacy of Infliximab for Treating Takayasu Arteritis

Zdenko Killinger MD<sup>1</sup>, Daniel Čierny MD<sup>1</sup>, Peter Jackuliak MD<sup>1</sup>, Zuzana Zelinkova MD<sup>1</sup>, Jozef Rovensky MD<sup>2</sup> and Juraj Payer MD<sup>1</sup>

<sup>1</sup>Fifth Department of Internal Medicine, Medical faculty of Comenius University, University Hospital Bratislava, Slovakia

<sup>2</sup>National Institute of Rheumatic Diseases, Piešťany, Slovakia

**KEY WORDS:** vasculitis, Takayasu arteritis, tumor necrosis factor-alpha (TNFα) inhibition, infliximab

IMAJ 2012; 14: 771–773

**For Editorial see page 757**

**V**asculitis is an inflammatory condition of autoimmune etiology affecting the vessel wall. Clinical signs are induced by the presence of ischemia in affected tissues and its intensity depends on the size and location of affected vessels as well as on the development of thromboembolic complications. Takayasu arteritis affects large vessels, particularly the aorta and its branches, mainly in young individuals. The clinical symptoms and signs are primarily claudication, absence of peripheral pulsations, difference in blood pressure between arms, or presence of murmurs over the narrowed parts of the aorta [1]. Diagnosis is based on arteriographic or ultrasound evidence of the occlusions, clinical manifestations, or laboratory markers of inflammation according to established diagnostic criteria. Treatment consists of glucocorticoids and immunosuppressive drugs, such as azathioprine, methotrexate and cyclophosphamide, in pulses. Recently, promising findings were reported with the use of infliximab for therapy-resistant phenotypes [2]. The prognosis depends mainly on the extent and localization of the vascular stenosis and on the development of complications, such as renovascular hypertension, cerebral ischemic attacks and aneurysms.

## PATIENT DESCRIPTION

Takayasu arteritis was diagnosed in a 25 year old woman at the stage of hemodynamically significant stenoses of both common carotid arteries and the aortic arch branches. The pitfalls in diagnostics and the reasons for late diagnosis of this disorder were reported previously. In our patient the initial symptoms were mostly non-specific and included weakness, arthralgia, subfebrilities, and later, upper limb muscle pain after physical activity. Blood pressure in the upper limbs could not be measured due to severe arterial stenotic changes; blood pressure in the lower limbs was 140/85. High levels of C-reactive protein (123 mg/L) and erythrocyte sedimentation rate (135/hour) as well as anemia (89 g/L) were detected.

Initially, treatment consisted of pulse therapy with methylprednisolone followed by prednisone 60 mg orally per day and concomitant cyclophosphamide at a dose of 50 mg per day. Stenting of both common carotid arteries was then performed due to critical stenoses (diameter 1.2 mm, bilateral).

One month of pulse glucocorticoid treatment (solumedrol 750 mg five times every second day) and cyclophosphamide led to significant remission of subjective symptoms, reduction in the general weakness and lessening of pain in the arms and back. Humoral activity (CRP, ESR) decreased by approximately 70% (CRP 36.9 mg/L, ESR 40/hour). However, ultrasound showed no improvement in the affected aortic arch branches.

CRP = C-reactive protein  
ESR = erythrocyte sedimentation rate

After 6 months of treatment an increase in clinical and humoral activity was noted. Pulse therapy with glucocorticoids was administered again, and the dose of cyclophosphamide was increased to 100–150 mg/day which was complicated by the development of side effects (dyspepsia, heartburn, metrorrhagia and alopecia). Intravenous administration of cyclophosphamide at a dose of 1000 mg/m<sup>2</sup> in monthly pulses was not tolerated either and the therapy was changed to azathioprine 50 mg/day. Gastrointestinal intolerance of this treatment, due to the persistently high humoral activity, prompted treatment with cyclosporine A (2 mg/kg) which was complicated by nephrotoxicity and hypertension. There was no clinical benefit with this treatment, and methotrexate at a dose of 10–15 mg per week was introduced. Due to adverse side effects (elevated liver enzymes, alopecia), higher doses could not be given. The patient was concomitantly treated with prednisone (20–40 mg/day). This treatment was ineffective, as evidenced also by persistent humoral activity and progressive stenosing of the abdominal aorta on ultrasound and computed tomography-angiography. Because of hemodynamically significant stenoses of renal arteries and celiac trunk with stenosis of the superior mesenteric artery, several angiosurgical procedures were performed; these included percutaneous transluminal angioplasty of the right renal artery, stenting of the celiac trunk, and aortorenal bypass on the right side.

At this stage, due to the persistent disease activity and progressive vessel involvement, treatment with anti-tumor

necrosis factor was considered. Based on published studies on the success of TNF $\alpha$  inhibitors in treating Takayasu arteritis and after obtaining the patient's informed consent, infliximab 3 mg/kg body weight was administered at 8 week intervals. Concomitant medication included methotrexate 7.5 mg/week, prednisone 20 mg/day and anti-aggregation drugs clopidogrel (75 mg/day) and sulodexide (250 lipasemic units/day).

After 3 months of therapy with infliximab claudication, there was a marked reduction in the patient's weakness and fatigue. Levels of CRP and ESR decreased by more than 50% compared to the previous non-biological disease-modifying anti-rheumatic drugs, but remained above the normal range (25–35 mg/L) [Figure]. However, after 4–6 weeks of this regimen the beneficial effects were beginning to wane; in view of this finding and the still elevated CRP levels we increased our monitoring of laboratory and clinical activity between treatments. We observed a significantly lower CRP concentration

(9–15 mg/L) 14 days after infliximab administration compared to levels after 2 months (25–35 mg/L). Based on this observation (clinical and laboratory), the interval between drug administrations was shortened to 6 weeks, which led to a further CRP decrease (15–25 mg/L). The therapy was well tolerated and there were no clinical or laboratory adverse side effects during 30 months of treatment. Control ultrasound and angiography showed amelioration of subclavian artery stenosis. These changes were noted as early as 6 months after initiation of anti-TNF treatment. The state of the abdominal aorta branches remained stable and no further surgical intervention was needed.

**COMMENT**

The development of TA in our patient was characterized by intense disease activity, rapid progress of stenoses, and resistance to classical DMARDs. The inadequate effect of the non-biological DMARDs

could be attributed to the aggressive disease course, the delay in diagnosis and the low dose of the immunosuppressive medication. Due to intolerance and the development of adverse side effects, the patient received on average approximately 50% of the maximal doses respective to her body weight. Additionally, the medication was administered for less than 3–5 months; only methotrexate and cyclophosphamide were administered for a longer time, though in reduced doses.

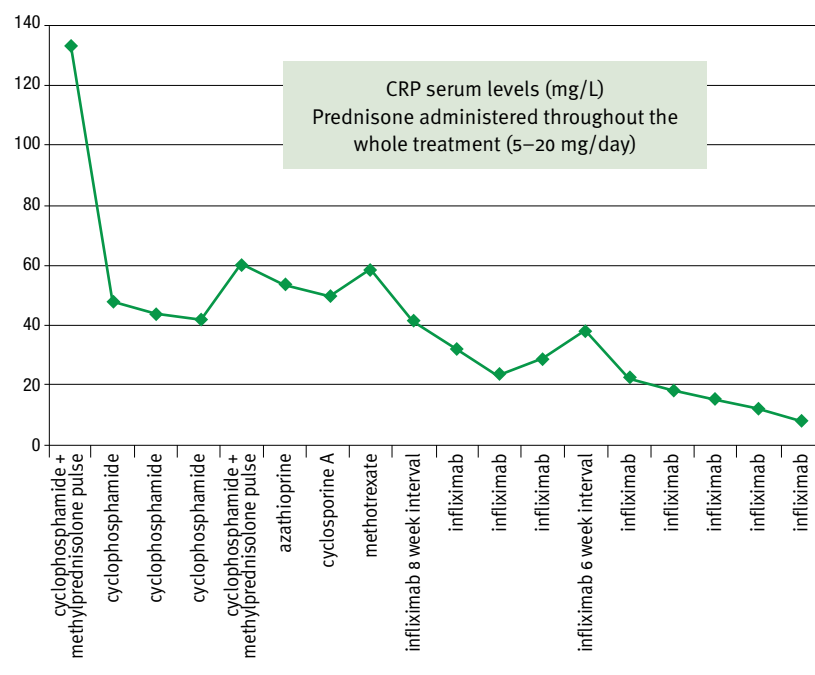
The lack of benefit with the non-biological DMARDs, the progressive hemodynamically significant stenoses, and the poor prognosis led to the introduction of biological therapy. Considering the published case studies where most patients were treated with infliximab at that time (2009), we chose this TNF $\alpha$  inhibitor.

The first case series on TNF $\alpha$  inhibitor treatment of Takayasu arteritis was reported by Hoffman et al. in 2004 [3]. In their study, 14 of 15 patients with steroid-resistant arteritis responded to anti-TNF therapy. The treatment regimen they used comprised an initial dose of 3–5 mg/kg infliximab according to the standard dosing regimen of week 0, 2 and 6 with subsequent infusion every 8 weeks. This was the regimen in our patient as well. Later in the follow-up, most of the patients in the cited case series required higher doses, as in our patient. In addition, a recently published case series of 15 patients showing 73% efficacy at 12 months follow-up also used an intensified regimen of a median of 6 week intervals between infliximab infusions [4]. Thus, the dose of infliximab necessary to maintain the arteritis in remission in the long term seems to be higher than in other rheumatologic conditions. Whether this greater need for TNF $\alpha$  blockade is related to a particular pathogenetic mechanism of Takayasu arteritis or to specific pharmacokinetics of infliximab with an increased immunogenic profile in these particular patients remains to be elucidated. Studies analyzing the infliximab trough levels and presence

TNF $\alpha$  = tumor necrosis factor-alpha

DMARD = disease-modifying antirheumatic drugs

CRP serum levels during the treatment



of anti-infliximab antibodies in patients on long-term infliximab treatment for Takayasu arteritis will therefore be of special interest.

Since this first report, more experience has been gained with the use of infliximab for Takayasu arteritis including long-term follow-up data [3-5]. Infliximab has been used for other immune mediated conditions in rheumatology (psoriatic arthropathy, ankylosing spondylitis) and in gastrointestinal diseases for several years. Its safety and efficacy in long-term use in these particular groups of patients as well as the long-term use of infliximab in

Takayasu arteritis seems to be safe. Thorough documentation of cases such as the one we report here is highly needed

**Corresponding author:**

**Dr. J. Rovenský**

National Institute of Rheumatic Diseases, Nábřežie Ivana Krasku 4, 921 12 Piešťany, Slovak Republic

**email:** jozef.rovensky@nurch.sk

**References**

1. Caspary L. Vasculitides of large vessels. *Vasa* 2011; 40 (2): 89-98.
2. Comarmond C, Plaisier E, Dahan K, et al. Anti TNF-α in refractory Takayasu's arteritis: cases

series and review of the literature. *Autoimmun Rev* 2012; 11(9): 678-84.

3. Hoffman GS, Merkel PA, Brasington RD, Lenschow DJ, Liang P. Anti-tumor necrosis factor therapy in patients with difficult to treat Takayasu arteritis. *Arthritis Rheum* 2004; 50 (7): 2296-304.
4. Mekinian A, Néel A, Sibilia J, et al; Club Rhumatismes et Inflammation, French Vasculitis Study Group and Société Nationale Française de Médecine Interne. Efficacy and tolerance of infliximab in refractory Takayasu arteritis: French multicentre study. *Rheumatology (Oxford)* 2012; 51 (5): 882-6.
5. Schmidt J, Kermani TA, Bacani AK, Crowson CS, Matteson EL, Warrington KJ. Tumor necrosis factor inhibitors in patients with Takayasu arteritis: experience from a referral center with long-term followup. *Arthritis Care Res (Hoboken)* 2012 ;64 (7): 1079-83.

**Capsule**

**Androgenetic haploid embryonic stem cells produce live transgenic mice**

Haploids and double haploids are important resources for studying recessive traits and have large impacts on crop breeding, but natural haploids are rare in animals. Mammalian haploids are restricted to germline cells and are occasionally found in tumors with massive chromosome loss. Recent success in establishing haploid embryonic stem (ES) cells in medaka fish and mice raised the possibility of using engineered mammalian haploid cells in genetic studies. However, the availability and functional characterization of mammalian haploid ES cells are still limited. Li et al. show that mouse androgenetic haploid ES (ahES) cell lines can be established by transferring sperm into an enucleated oocyte. The ahES cells maintain haploidy and stable growth over 30 passages,

express pluripotent markers, possess the ability to differentiate into all three germ layers in vitro and in vivo, and contribute to germlines of chimeras when injected into blastocysts. Although epigenetically distinct from sperm cells, the ahES cells can produce viable and fertile progenies after intracytoplasmic injection into mature oocytes. The oocyte injection procedure can also produce viable transgenic mice from genetically engineered ahES cells. These findings show the developmental pluripotency of androgenetic haploids and provide a new tool to quickly produce genetic models for recessive traits. They may also shed new light on assisted reproduction.

*Nature* 2012; 490: 407

Eitan Israeli

**Capsule**

**MR1 presents microbial vitamin B metabolites to MAIT cells**

Antigen-presenting molecules, encoded by the major histocompatibility complex (MHC) and CD1 family, bind peptide- and lipid-based antigens, respectively, for recognition by T cells. Mucosal-associated invariant T (MAIT) cells are an abundant population of innate-like T cells in humans that are activated by an antigen(s) bound to the MHC class I-like molecule MR1. Although the identity of MR1-restricted antigen(s) is unknown, it is present in numerous bacteria and yeast. Kjer-Nielsen et al. show that the structure and chemistry within the antigen-binding cleft of MR1 is distinct from the MHC and CD1 families. MR1 is ideally suited to bind ligands originating from vitamin metabolites. The structure of MR1 in complex with

6-formyl pterin, a folic acid (vitamin B9) metabolite, shows the pterin ring sequestered within MR1. Furthermore, the authors characterize related MR1-restricted vitamin derivatives, originating from the bacterial riboflavin (vitamin B2) biosynthetic pathway, which specifically and potently activate MAIT cells. Accordingly, they show that metabolites of vitamin B represent a class of antigen that are presented by MR1 for MAIT-cell immunosurveillance. As many vitamin biosynthetic pathways are unique to bacteria and yeast, these data suggest that MAIT cells use these metabolites to detect microbial infection.

*Nature* 2012; doi:10.1038/nature11605

Eitan Israeli