

Nailfold Video Capillaroscopy: Beyond Systemic Sclerosis

Doron Rimar MD, Ori Rimar, Itzhak Rosner MD, Michael Rozenbaum MD, Lisa Kaly MD, Nina Boulman MD and Gleb Slobodin MD

Rheumatology Unit, Bnai Zion Medical Center, affiliated with Rappaport Faculty of Medicine, Technion–Israel Institute of Technology, Haifa, Israel

KEY WORDS: nailfold video capillaroscopy, microvasculature, rheumatic diseases, systemic sclerosis, vasculitis

IMAJ 2019; 21: 499–502

Capillaroscopy is a non-invasive, diagnostic tool designed to enable clinicians to evaluate microcirculation. In 1663, Johan Christophorus Kolhaus was the first clinician to use a primitive microscope to observe the small blood vessels surrounding the nails. Giovanni Rasori (1776–1873), using a magnifying glass, first reported the close relationship between conjunctival inflammation and the presence of an inextricable knot of capillaries [1]. In 1862, Maurice Raynaud (1834–1881) presented his thesis in Paris on local ischemic damage of the hands, feet, nose, and tongue that became the early crucial vascular signs of several autoimmune diseases and was named “Raynaud’s phenomena” [2]. In 1911, W.P. Lombard discovered that using a microscope, after the application of a drop of immersion oil, periungual capillaries could be observed in humans [3]. In 1916, W. Weiss standardized the capillaroscopic technique and was able to take pictures of the capillaries using a primordial camera. Finally, in 1925, G.E. Brown and P.A. O’Leary used capillaroscopic analysis to show in detail the abnormalities that are characteristic to systemic sclerosis associated Raynaud’s phenomena [1].

The last century was characterized by the optimization of capillaroscopic tools. Since 1990, nailfold video capillaroscopy (NVC) with a standard $\times 200$ fold magnification, has replaced the older widefield microscopy technique (low magnification $\times 12$), thus enabling clinicians to digitally capture, measure, and compare nailfold microvascular changes in real time. This diagnostic technique was quickly embraced by systemic sclerosis (SSc) experts, and Cutolo et al. [1] defined three patterns of SSc.

SSc patterns include:

- Early NVC patterns: few enlarged/giant capillaries, few capillary hemorrhages, relatively well-preserved capillary distribution, no evident loss of capillaries
- Active NVC patterns: frequent giant capillaries, frequent capillary hemorrhages, moderate loss of capillaries, mild

disorganization of the capillary architecture, absent or mild ramified capillaries

- Late NVC patterns: irregular enlargement of the capillaries, few or absent giant capillaries as well as hemorrhages, severe loss of capillaries with extensive avascular areas, disorganization of the normal capillary array, ramified/bushy capillaries

The most specific abnormality in SSc is giant capillaries, which includes homogeneous capillary widening of more than $50 \mu\text{m}$ [4]. In 2013, a scleroderma pattern was finally included as one of the defining classification criteria of SSc, and this definition has become a standard diagnostic tool in SSc [5]. Although the scleroderma pattern is highly specific for SSc, similar findings can be seen in dermatomyositis, mixed connective tissue disease, or overlap syndrome in a different clinical context.

WHY NAILFOLD VIDEO CAPILLAROSCOPY?

NVC is a form of intravital microscopy that enables clinicians to look at the microvasculature in real time without the need for a biopsy. Three sites are approachable for intravital microscopy in humans: the small arterioles of the retina inspected by an ophthalmoscope; the sublingual microcirculation, which has been studied by many techniques but poses a great deal of technical difficulty and thus low quality; and the nailfold, which is convenient, approachable, and practical for evaluation and thus has been studied most in rheumatology.

PATHOPHYSIOLOGY OF MICROANGIOPATHY

Our understanding of microvasculature involvement in SSc is extensive, but many other rheumatic diseases share some of these aspects of vascular pathology and involve neoangiogenesis and vasculopathy.

In SSc, dysregulation of apoptosis and proliferation within the vascular wall play important roles in vascular remodeling associated with fibroproliferative vasculopathy. Multiple studies have shown that antiendothelial antibodies (AECA) might be responsible for mediating this endothelial cell injury through antibody-dependent cell-mediated cytotoxicity (ADCC) [6]. It is suggested that this ADCC is induced via the Fas pathway. Upregulation of adhesion molecule expression (E-selectin, intercellular adhesion molecule 1 [ICAM-1], and VCAM-1)

and increased leukocyte adhesion following AECA binding has also been shown to be an AECA binding effect. Endothelial cells in SSc lose their potential to participate in a normal angiogenesis process in response to endothelial cells injury [6]. Many biomarkers suggestive for dysfunctional angiogenesis in relation to overexpression of pro-angiogenic mediators are suggested, namely VEGF, VEGFR-2, and CXCL8. Despite elevation of VEGF in plasma and skin, adaptive angiogenesis is absent, and a progressive loss of capillaries is observed [7]. This paradox is further supported by the knowledge that short-time upregulation of VEGF is a strong inducer of angiogenesis, while chronic and uncontrolled overexpression of VEGF, which occurs in SSc, leads to the formation of irregularly shaped sac-like vessels with reduced blood flow in the newly formed vessels (giant capillaries).

Distler and colleagues [8] noted an increase in VEGF in SSc patients that appeared to be the result of a significant increase in the anti-angiogenic VEGF165b isoform instead of VEGF165. Further disrupted angiogenesis in SSc is mediated by upregulated endostatin, an angiogenesis inhibitor, and by the dysregulation of vascular tone including vasodilator and nitric oxide as well as the upregulation of the vasoconstrictor endothelin 1, which is considered a hallmark of SSc vasculopathy [7].

Damaged endothelial cells release several molecular substances into blood circulation that interfere with coagulation homeostasis and activate platelets. Impairment of the coagulation system is manifested by the presence of circulating supra-normal multimers of von Willebrand factor (vWF) or elevated levels of vWF, factor VIII antigen, fibrinogen, thrombomodulin, tissue plasminogen activator, and plasminogen activator inhibitor 1 [9].

MICROANGIOPATHY AND NVC IN RHEUMATIC DISEASES OTHER THAN SSC

SSc is the most widely known autoimmune disease to manifest capillary changes in the nailfold; however, many other rheumatic diseases have been described that share some features of vasculopathy. Nonspecific NVC changes have been described in systemic lupus erythematosus, antiphospholipid syndrome, rheumatoid arthritis, Sjögren syndrome, psoriatic arthritis, familial Mediterranean fever, and Behçet's disease [10,11].

NAILFOLD VIDEO CAPILLAROSCOPY IN VASCULITIS

Vasculitides are formally classified by artery size (large, medium, or small); yet, this distinction is not absolute. Even in the most distinctive large vessel vasculitis, Takayasu arteritis, vasculitis of the small retinal arteries, has been described [12]. Furthermore, it is not uncommon to diagnose small vessel vasculitis in the skin of a patient with polyarteritis nodosa that is classified as medium size vasculitis, a fact that is acknowledged in the Chapel Hill classification criteria. This criteria states that polyarteritis nodosa (PAN) and antineutrophil cytoplasmic

antibody-associated vasculitis can exhibit clinically and pathologically indistinguishable necrotizing arteritis of medium and small arteries [13]. Hence, we classify vasculitides by artery size as the main phenotype, but not the exclusive phenotype.

While in some patients diagnosis of vasculitis is straight forward and can be supported by tissue biopsy, imaging, or immune serologies, in other cases the diagnosis of vasculitis is elusive, the signs and symptoms are not specific, and biopsies are not feasible. In these cases, NVC enables us to get a direct glimpse at the culprit system – the vasculature.

RHEUMATOID VASCULITIS

One of the first descriptions of NVC in vasculitis was reported by Hachulla et al. [14]. That group evaluated patients with rheumatoid vasculitis. They did not find abnormalities in conventional capillaroscopy; however, using fluorescence videomicroscopy after intravenous injection of fluorescein sodium, they observed an increase of transcapillary dye diffusion in 9/9 patients.

In another study, rheumatoid arthritis patients with clinical signs of systemic vasculitis showed significantly higher levels of serum ICAM-1 than those without vascular involvement. Although no significant correlation between serum ICAM-1 levels and the capillaroscopy findings was found, 75% of the patients with severe vascular changes in capillaroscopy exceeded normal serum ICAM-1 cut off value [15].

Kuryliszyn-Moskal and colleagues [16] described 80 rheumatoid arthritis patients. Rheumatoid arthritis (RA) patients with clinical signs of systemic vasculitis showed significantly higher levels of TNF-alpha and Interleukin 6 (IL-6) compared to those without vascular involvement. All patients with signs of extra-articular manifestations manifested with severe or moderate changes in nailfold capillaroscopy, namely extravasations into perivascular tissue and extensive visible subpapillary venous plexus [16].

PRIMARY AUTOIMMUNE VASCULITIDES

Several small-scale studies have reported findings in adults with autoimmune vasculitis, although most of them were uncontrolled and had been conducted using a light microscope and not NVC. Sendino et al. [17] reported their observations of using light microscope capillaroscopy in 15 patients with vasculitis. Two presented with classic PAN, three had eosinophilic granulomatosis with polyangiitis, two had hypersensitivity vasculitis, six had giant-cell arteritis, and two had granulomatosis with polyangiitis (GPA). They reported microhemorrhages, seen in 73% of patients, yet concluded that there was no added value in capillaroscopy in vasculitis. Two other studies evaluated a more homogeneous group of patients with GPA. In 2000, Anders and colleagues [18] reported that in 12 patients with GPA, 92% had nailfolds with avascular areas and 50% with microhemorrhages. Uceda and colleagues [19] discussed an observational study of 10 patients with GPA using NVC. In

that study, 50% of patients exhibited hemorrhage (single or multiple), 37.5% avascular areas, and 75% lower capillary density. Javinani and co-authors [20] reported on an observational prospective case-control study of 15 patients with Takayasu arteritis compared to healthy controls using NVC. The authors found lower capillary length, and venous limb diameter and higher rates of tortuous capillaries in patients with Takayasu arteritis compared to healthy control cases.

NAILFOLD VIDEO CAPILLAROSCOPY IN PEDIATRIC VASCULITIS

Two studies describe NVC in pediatric population with Henoch schonlein purpura using light microscopy. A study of 31 cases reported by Martino and colleagues [21] described tortuosity in 100% of patients, edema in 60%, branching capillaries in 50% (decreased to 20% after 1 year of follow-up), sludging in 20%, and granular appearance of capillary wall in 30%. Zampetti et al. [22] reported reduction of capillaries density in 12 children (40%), disarrangement with avascular areas and neoangiogenesis in 6 (20%), abnormal capillaries in 14 (46.7%), increased capillary length in 12 (40%), microhemorrhages in 3 (10%), and severe edema in 23 (74.2%).

NEW INSIGHTS OF NAILFOLD VIDEO CAPILLAROSCOPY IN VASCULITIS

Overall, our understanding of capillary abnormalities in vasculitis is very limited as the studies that have been reported are mostly small, uncontrolled trials and were conducted with different methodologies and definitions. The most widely reported findings are microhemorrhages and avascular areas, which are not specific enough and are reported in the general healthy population as well [23]. A more specific pattern of active vasculitis is needed to utilize NVC as a diagnostic tool in vasculitis.

Recently our group initiated a controlled observational study of NVC in vasculitis using optilia mediscope with a ×200 magnification. Our preliminary results included two new insights that can help diagnosing vasculitis.

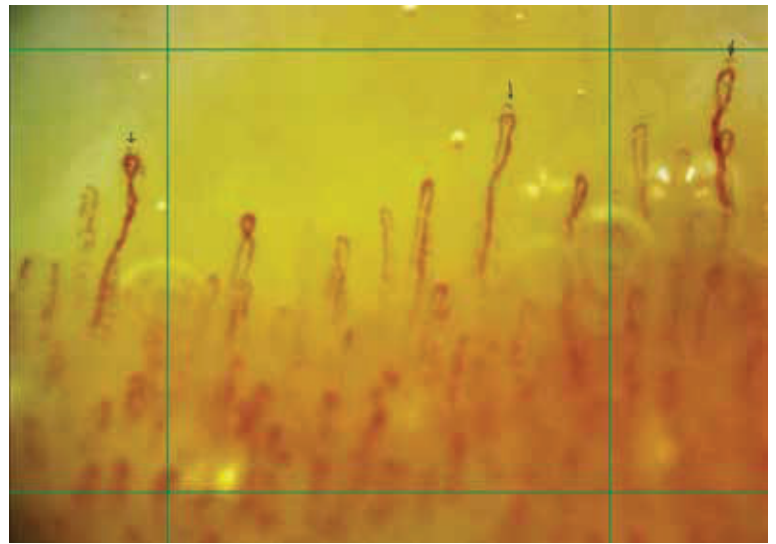
PERICAPILLARY STIPPLING

By inspecting hundreds of images of patients with vasculitis, we were able to diagnose a pattern that seemed to be specific to vasculitis, pericapillary stippling (PCS) [Figure 1]. PCS are small pigmented spots that can be observed, usually above the apical segment of the capillary, probably representing extravasation of red blood cells from leaky capillaries, that turned into hemosiderin. PCS was found in 30% of patients with active vasculitis and in none of the healthy controls, which thus seems to be a specific sign of vasculitis

ROLLING

Normally, capillaries should be seen in NVC with a homogenous and continues filling of red blood cells. In patients with

Figure 1. Nailfold video capillaroscopy ×200 showing capillaries with stippling near the apical segment of the capillaries (arrows), probably representing extravasation of red blood cells from leaky capillaries, that turned into hemosiderin



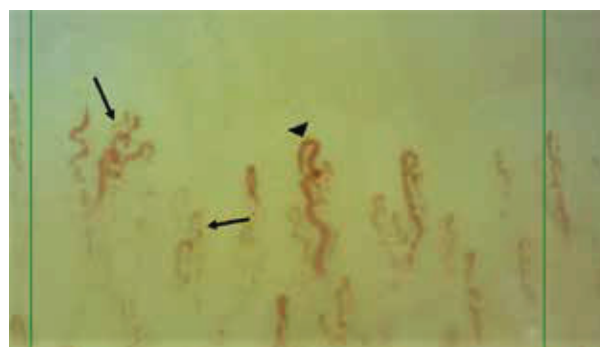vasculitis, we have been able to observe a disrupted flow of red blood cells that can be seen rolling slowly one by one within the capillary, even when only light pressure is applied with the capillaroscope [Figure 2]. This abnormal flow has been found in 75% of patients with vasculitis and only in 12% of healthy controls.

Other capillary abnormalities, such as neoangiogenesis and avascular areas, have been observed as well. We are currently trying to define a vasculitis capillaroscopic pattern that will have high specificity and will be of use as an additive diagnostic tool in vasculitis.

CONCLUSIONS

NVC is an available, easy-to-use, diagnostic tool that enables clinicians to inspect the microvasculature, intravitaly. The use

Figure 2. Nailfold video capillaroscopy ×200 showing capillaries with disrupted flow of red blood cells, flowing one by one, rolling (arrows), in contrast to the normal distended capillary (arrow head)



of NVC as a diagnostic tool in SSc is well-established, yet it seems that microcirculation is involved in many other rheumatic diseases. The use of NVC in the diagnosis of vasculitis is of great interest as it enables doctors to inspect in real-time the culprit system and to obtain morphological as well as qualitative hemodynamic insights. Our understanding of NVC abnormalities in vasculitis is very limited and research is lacking. Microhemorrhages and avascular areas are the common findings in vasculitis. We suggest two new techniques to be further evaluated in patients with vasculitis: PCS, which may represent leaky capillaries, and rolling phenomena, which may be attributed to vasculopathy and sludging of red blood cell within the capillaries. Further research is needed in the field of NVC in vasculitis to define a vasculitis capillaroscopic patterns that could help in the diagnosis of vasculitis.

Correspondence

Dr. D. Rimar

Rheumatology Unit, Bnai Zion Medical Center, Haifa 38041, Israel

Phone: (972-4) 835-9997

Fax: (972-4) 837-2898

email: doronrimar@gmail.com

References

- Cutolo M, Smith V. State of the art on nailfold capillaroscopy: a reliable diagnostic tool and putative biomarker in rheumatology? *Rheumatology (Oxford)* 2013; 52 (11): 1933-40.
- Raynaud M. De l'asphyxie locale et de la gangrène symétrique des extrémités. Paris: Leclerc; 1862.
- Lombard W. P. The blood pressure in the arterioles, capillaries and small veins of the human skin. *Am J Physiol* 1912; 29 (3): 335-62.
- Koenig M, Joyal F, Fritzler MJ, et al. Autoantibodies and microvascular damage are independent predictive factors for the progression of Raynaud's phenomenon to systemic sclerosis: a twenty-year prospective study of 586 patients, with validation of proposed criteria for early systemic sclerosis. *Arthritis Rheum* 2008; 58: 3902-12.
- Van den Hoogen F, Khanna D, Fransen J, et al. Classification criteria for systemic sclerosis: an American College of Rheumatology/European League against Rheumatism Collaborative Initiative. *Arthritis Rheum* 2013; 65 (11): 2737-47.
- Cutolo M, Smith V. State of the art on nailfold capillaroscopy: a reliable diagnostic tool and putative biomarker in rheumatology? *Rheumatology (Oxford)* 2013; 52 (11): 1933-40.
- Liakouli V, Cipriani P, Marrelli A, Alvaro S, Ruscitti P, Giacomelli R. Angiogenic cytokines and growth factors in systemic sclerosis. *Autoimmun Rev* 2011; 10 (10): 590-4.
- Distler O, Distler JH, Scheid A, et al. Uncontrolled expression of vascular endothelial growth factor and its receptors leads to insufficient skin angiogenesis in patients with systemic sclerosis. *Circ Res* 2004; 95 (1): 109-16.
- Kanno Y. The role of fibrinolytic regulators in vascular dysfunction of systemic sclerosis. *Int J Mol Sci* 2019; 20 (3): pii: E619.
- Cortes S, Cutolo M. Capillaroscopic patterns in rheumatic diseases. *Acta Reumatol Port* 2007; 32 (1): 29-36.
- Aytekin S, Yuksel EP, Aydin F, et al. Nailfold capillaroscopy in Behçet disease, performed using videodermoscopy. *Clin Exp Dermatol* 2014; 39 (4): 443-7.
- Bajgai P, Singh R. Retinal vasculitis in Takayasu's arteritis. *N Engl J Med* 2018; 378 (21): e28.
- Jennette JC, Falk RJ, Bacon PA, et al. 2012 revised International Chapel Hill Consensus Conference Nomenclature of Vasculitides. *Arthritis Rheum* 2013; 65 (1): 1-11.
- Hachulla E, Perez-Cousin M, Flipo RM, et al. Increased capillary permeability in systemic rheumatoid vasculitis: detection by dynamic fluorescence nailfold videomicroscopy. *J Rheumatol* 1994; 21 (7): 1197-202.
- Kuryliszyn-Moskal A, Bernacka K, Klimiuk PA. Circulating intercellular adhesion molecule 1 in rheumatoid arthritis--relationship to systemic vasculitis and microvascular injury in nailfold capillary microscopy. *Clin Rheumatol* 1996; 15 (4): 367-73.
- Kuryliszyn-Moskal A. Cytokines and soluble CD4 and CD8 molecules in rheumatoid arthritis: relationship to systematic vasculitis and microvascular capillaroscopic abnormalities. *Clin Rheumatol* 1998; 17 (6): 489-95.
- Sendino Revuelta A, Barbado Hernández FJ, Torrijos Eslava A, et al. Capillaroscopy in vasculitis. *An Med Interna* 1991; 8 (5): 217-20. [Spanish].
- Anders HJ, Headecke C, Sigl T, Kruger K. Avascular areas on nailfold capillary microscopy of patients with Wegener's granulomatosis. *Clin Rheumatol* 2000; 19: 86-8.
- Uceda J, Martinez R, Velloso M, et al. Periungual capillaroscopy findings in a series of patients with granulomatosis with polyangiitis (Wegener): an observational study. *Open J Rheumatol Autoimmune Dis* 2013; 3: 130-4.
- Javinani A, Pournazari M, Jamshidi AR, Kavosi H. Nailfold videocapillaroscopy changes in Takayasu arteritis and their association with disease activity and subclavian artery involvement. *Microvasc Res* 2019; 122: 1-5.
- Martino F, Agolini D, Tsalikova E, et al. Nailfold capillaroscopy in Henoch-Schönlein purpura: a follow-up study of 31 cases. *J Pediatr* 2002; 141 (1): 145.
- Zampetti A, Rigante D, Bersani G, Rendeli C, Feliciani C, Stabile A. Longitudinal study of microvascular involvement by nailfold capillaroscopy in children with Henoch-Schönlein purpura. *Clin Rheumatol* 2009; 28 (9): 1101-5.
- Ingegnoli F, Gualtierotti R, Lubatti C, et al. Nailfold capillary patterns in healthy subjects: a real issue in capillaroscopy. *Microvasc Res* 2013; 90: 90-5.

Capsule

Mapping human microbiome drug metabolism by gut bacteria and their genes

Individuals vary widely in their responses to medicinal drugs, which can be dangerous and expensive owing to treatment delays and adverse effects. Although increasing evidence implicates the gut microbiome in this variability, the molecular mechanisms involved remain largely unknown. Zimmermann and colleagues showed, by measuring the ability of 76 human gut bacteria from diverse clades to metabolize 271 orally administered drugs, that many drugs are chemically modified by microorganisms. The authors combined high-throughput genetic analyses with mass spectrometry to systematically identify microbial gene products that metabolize drugs. These

microbiome-encoded enzymes can directly and substantially affect intestinal and systemic drug metabolism in mice. This effect can explain the drug-metabolizing activities of human gut bacteria and communities on the basis of their genomic contents. These causal links between the gene content and metabolic activities of the microbiota connect interpersonal variability in microbiomes to interpersonal differences in drug metabolism, which has implications for medical therapy and drug development across multiple disease indications.

Nature 2019; 570: 462

Eitan Israeli