

Retinal Vascular Occlusion following Traumatic Hyphema and Glaucoma, as a Presenting Sign of Sickle Cell Trait

Alvit Wolf MD, Mordechai Shalem MD, Josepha Horowitz MD and Orna Geyer MD

Department of Ophthalmology, Carmel Medical Center, Haifa, Israel

Key words: sickle cell trait, hyphema, retinal vascular occlusion, increased intraocular pressure

IMAJ 2005;7:476-477

We present a case of glaucoma secondary to traumatic hyphema that resulted in the appearance of retinal vascular occlusions. The retinal pathology suggested the diagnosis of sickle cell trait.

Sickle cell disease affects primarily black Africans and Afro-Americans but is also found in Mediterranean countries and in a number of Arab communities in Israel. The gene for hemoglobin S is inherited in an autosomal recessive manner. The heterozygous form (HbSA), with only half of the DNA affected by the genetic change, is usually asymptomatic. Although sickle cell trait has traditionally been considered by ophthalmologists to be a benign condition, retinal vascular occlusions have been reported in carriers suffering from hyphema and persistently high intraocular pressure [1]. In our patient, persistent elevation of IOP secondary to traumatic hyphema and retinal pathology were the presenting signs of the sickle cell trait.

Patient Description

A 35 year old healthy Arab male presented with hyphema and elevated IOP following blunt trauma to his right eye. Ocular examination of the right eye revealed visual acuity of light perception, IOP 45 mmHg, and hyphema filling two-thirds of the anterior chamber. The fundus was not visible. Visual acuity of the left eye was 20/20, IOP was 14 mmHg, and examination of the anterior and posterior segment was normal.

Two weeks later intraocular pressure was controlled with medications including timolol 0.5%, brimonidine 0.2% and

acetazolamide. The hyphema was mostly absorbed and the visual acuity improved to 20/70. Gonioscopy revealed an open angle and no angle recession was seen; the optic disk was normal and retinal examination was unremarkable. The patient was instructed to continue glaucoma medications.

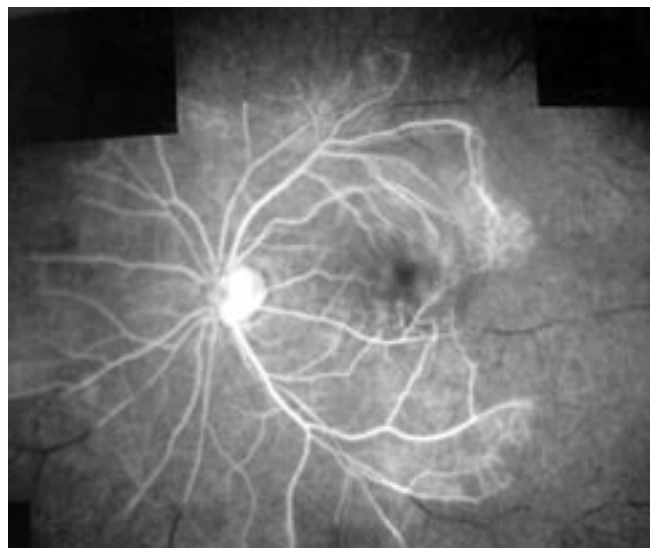
He was lost to follow-up and seen again 2 months later. At that time, visual acuity of the right eye was finger count to 1.5 meters, IOP was 42 mmHg, and fundus examination showed total excavation of the optic nerve and multiple retinal arteriolar and venous occlusions. Fluorescein angiography of the right eye documented the occlusion of peripheral retinal arteries and veins [Figure]. Sickle cell hemoglobinopathy was suspected and confirmed by hemoglobin electrophoresis (hemoglobin S 39.5% and hemoglobin A 57.5%). Filter operation controlled the intraocular pressure.

Eight months later visual acuity in the right eye was 20/200; IOP was 18 mmHg without pharmacologic treatment. The anterior segment was normal and retinal examination revealed total cupping of the optic nerve head and occlusion of peripheral retinal arteries and veins. Examination of the left eye was normal with visual acuity of 20/20 and IOP of 15 mmHg.

Comment

Sickle cell disease affects primarily black Africans and Afro-Americans but is also found in Mediterranean countries. The gene for hemoglobin S is inherited in an autosomal recessive manner.

Patients with sickle cell disease are known to manifest a range of ocular signs such as comma-shaped vessels in the bulbar conjunctiva, iris atrophy, and iris neovascularization. Also, in the posterior segment, signs such as retinal venous tortuosity and non-proliferative retinopathy are frequently seen. Further signs include black sunbursts (retinal pigment epithelial hyperplasia secondary to deep retinal vascular occlusions), glistening retractile deposits in the retinal periphery (hemosiderin-laden macrophages), salmon patch hemorrhages (orange-pink-colored intraretinal hemorrhage), angioid streaks, retinal vascular occlusions, peripheral neovascularization



Fluorescein angiogram showing multiple retinal arteriolar and venous occlusions

IOP = intraocular pressure

(seafan retinopathy), and subsequent vitreous hemorrhage with development of tractional retinal detachment.

The heterozygous form (HbSA), with only half of the DNA affected by the genetic change, is usually asymptomatic. Sick cell trait has traditionally been considered by ophthalmologists to be a benign condition, although retinal vascular occlusions have been described in carriers with hyphema and persistently high intraocular pressure [1]. Blunt ocular injury is associated with anterior chamber hemorrhage and formation of hyphema due to globe compression and rupture of the iris or ciliary body vessels. Approximately one-third of all hyphema patients exhibit increased intraocular pressure most commonly secondary to occlusion of the trabecular meshwork by erythrocytes and debris, or rarely due to pupillary block by a blood clot. However, trauma to the anterior chamber angle in the form of angle recession or trabecular damage can also cause a rise in intraocular pressure.

Patients suffering from sickle cell hemoglobinopathies and hyphema have an increased risk of developing elevated intraocular pressure as well as rebleeding compared to non-sickle cell patients [2]. In the presence of hyphema, red blood cells containing HbSA will sickle in the anterior chamber due to a more hypoxic and acidic environment than plasma. The sickled erythrocytes occlude the trabecu-

lar meshwork, increasing the intraocular pressure [3]. The elevated IOP induces stagnation of erythrocytes in ocular vessels, causing excessive deoxygenation and sickling. The sickled erythrocytes raise blood viscosity and reduce blood flow, increasing the risk for retinal vessel occlusion and optic nerve infarction [4]. Meanwhile, the elevated IOP decreases perfusion to the anterior chamber, causing more hypoxia, more cycling and a further increase in IOP – precipitating this cycle of destruction. Aggressive therapy to control IOP is indicated in these patients; however, acetazolamide should be avoided since it causes systemic acidosis which potentiates sickling. Anterior chamber paracentesis is the most effective treatment to control IOP in this case [4].

In our previously healthy patient, the occlusion of peripheral retinal arteries and veins that accompanied the persistent elevation of IOP following traumatic hyphema suggested the diagnosis of sickle cell trait.

Retinal vascular occlusion is a known complication of traumatic hyphema and glaucoma in patients previously diagnosed as carriers of the sickle cell trait [3–5]. However, to the best of our knowledge it has never been described in a previously healthy individual, suggesting the diagnosis of sickle cell trait, as in our case. We therefore recommend that patients with persistent increase in IOP

secondary to hyphema, and who have the appropriate ethnic background, be tested for the presence of sickle cell trait. If the diagnosis is confirmed, prompt treatment to control IOP should be undertaken to minimize the risk of retinal vascular occlusion.

References

1. Michelson PE, Pfaffenbach D. Retinal arterial occlusion following ocular trauma in youths with sickle cell trait hemoglobinopathy. *Am J Ophthalmol* 1972;74:494–7.
2. Walton W, Von Hagen S, Grigorian R, Zarbin M. Management of traumatic hyphema. *Surv Ophthalmol* 2002;47:297–334.
3. Goldberg MF. Sickled erythrocytes, hyphema and secondary glaucoma. The diagnosis and treatment of sickled erythrocytes in human hyphemas. *Ophthalmol Surg* 1979;10:17–31.
4. Wax M, Ridley ME, Magargal LE. Reversal of retinal and optic disc ischemia in a patient with sickle cell trait and glaucoma secondary to traumatic hyphema. *Ophthalmology* 1982;89:845–51.
5. Ganesh A, al-Habsi NS, al-Alawi FK, Mitra S, Eriksson A, Venugopalan P. Traumatic hyphema and sickle cell retinopathy in a patient with sickle cell haemoglobin E (HbSE) disease. *Eye* 2000;14:397–400.

Correspondence: Dr. O. Geyer, Head, Dept. of Ophthalmology, Carmel Medical Center, 7 Michal Street, Haifa 34362, Israel.
Phone: (972-4) 825-0926
Fax: (972-4) 825-0492
email: Orna_Geyer@clalit.org.il