

Focal Asymmetric Breast Density: Mammographic, Sonographic and Pathological Correlation in 97 Lesions – A Call to Restrain Biopsies

Fani Sperber MD¹, Ur Metser MD¹, Andrea Gat MD³, Anat Shalmon MD¹ and Neora Yaal-Hahoshen MD²

Departments of ¹Radiology, ²Oncology and ³Pathology, Tel Aviv Sourasky Medical Center, Tel Aviv, Israel
Affiliated to Sackler Faculty of Medicine, Tel Aviv University, Ramat Aviv, Israel

Key words: asymmetry, breast, density, mammography, sonography

Abstract

Background: The imaging parameters that mandate further diagnostic workup in focal asymmetric breast densities are not clearly defined.

Objectives: To identify indications for further workup in FABD by comparing mammographic and ultrasonographic findings with the pathology results of women with FABD.

Methods: Ninety-four women (97 FABD) were referred for core needle biopsy after incidental discovery of FABD on routine mammograms (n=83) or on diagnostic mammograms performed for palpable masses (n=11). Clinical data included the patient's age, use of hormone replacement therapy, family history of breast cancer, and the presence of a palpable mass. Mammograms and sonograms were evaluated for lesion size and location, associated calcifications, architectural distortion, and change from previous examinations when available. Two patient groups emerged according to the pathological findings and the data were compared.

Results: The average age, size and location of the lesions in the malignant (n=5) and benign (n=92) groups were similar. There was a significant difference ($P < 0.05$) for the presence of a clinically palpable mass (60% vs. 9%, respectively), a cluster of calcifications (60% vs. 12%), associated architectural distortion (exclusively in the malignant group) and a solid mass on sonography (50% vs. 9%). The malignant group had a higher rate of family history of breast cancer and HRT use.

Conclusions: FABD usually present a benign etiology and can safely be managed by follow-up. The presence of an architectural distortion, a cluster of malignant-appearing or indeterminate calcifications, a sonographic mass with features of possible malignancy, or a clinically palpable mass mandates tissue diagnosis.

IMAJ 2007;9:720–723

Focal asymmetric breast densities is defined by the American College of Radiology Breast Imaging Reporting and Data System (BI-RADS) as "...asymmetry of tissue density with similar shape on two views but completely lacking borders and the conspicuity of a true mass..." [1]. It is found in approximately 3% of mammograms [2], although studies quantifying the prevalence of cancer in asymmetric breast tissue in a large series of patients are sparse. A review of the literature shows that malignancy can be found in 0–14% of asymmetric breast tissue biopsies [3-8]. In fact, FABD have been described in approximately 15% of mammograms with pathologically proven invasive lobular carcinomas

[9], in 4% of pure mucinous carcinomas of the breast [10], in 5% of tubular carcinomas of breast [11] and in primary breast lymphoma [12].

FABD have also been described in a wide range of benign entities, including pyogenic or tuberculous breast infection [13,14], focal breast fibrosis [15], pseudoangiomatous hyperplasia [2] and sclerosing lobular hyperplasia [16]. There has even been a case report of extramedullary hematopoiesis in the breast presenting as FABD [17], and approximately 4% of mammograms performed in postmenopausal women receiving hormonal replacement therapy may show FABD [18,19]. Data on ultrasonographic findings in breasts with FABD are scarce and the results of these studies are conflicting. One study of eight patients showed that most of their sonograms were normal [2], while another study of 15 patients found a sonographic abnormality in 6 cases [20].

The presence of a clinically palpable mass, associated architectural distortion, or clusters of calcifications increases the likelihood of malignancy [1]. Conversely, the absence of a palpable mass in an asymmetric density of over 16 mm speaks against malignancy, and it has been suggested that such lesions can be managed safely by follow-up [21].

To the best of our knowledge there are no published large series correlating mammographically detected FABD with sonographic and pathology findings. The purpose of this study was to review the spectrum of clinical, mammographic and sonographic findings of FABD and, upon correlation with pathology, to determine which parameters mandate further diagnostic workup.

Patients and Methods

A retrospective review of the biopsy database of our breast imaging clinic over a 28 month period (October 1998 to January 2001) identified 97 consecutive image-guided large core needle biopsies performed due to FABD in 94 women. Two of these 94 patients had two areas of FABD in the same breast and another one had one area of density in each breast. The lesions were found either on routine screening mammograms (n=83) or on diagnostic mammograms (n=11). The indications for performing biopsies included a clinically palpable mass (n=11), new or progressing asymmetry in comparison to a previous study (n=32), the presence of a solid mass on sonography (n=7), and associated worrisome radiological findings (n=5, two with architectural distortion and three with indeterminate or malignant calcifications). The rest were performed

FABD = focal asymmetric breast densities
HRT = hormone replacement therapy

at the request of the patient's surgeon – often due to patient concern – despite the absence of a clear indication for biopsy on imaging.

Imaging and biopsy technique

All mammograms were performed using the Seno DMR+ unit (GE Medical Systems, France). At least two conventional views were taken. Other views, including coned magnifications, were added at the request of the diagnostician. Mammographic size and area were determined in two dimensions using the view in which the size of the lesion was largest. All ultrasound examinations were performed with an Acuson 128XP/10 unit (Mountain View, CA, USA) using a 7.5–10 MHz transducer.

Ninety-five biopsies were performed stereotactically or ultrasound-guided using a 14-gauge core tissue biopsy needle with a Bard Magnum Biopsy Instrument (Covington, GA, USA). Two biopsies were performed using an 11-gauge core needle with a Mammotome probe (Ethicon Endo-Surgery, Inc., Cincinnati, OH).

Data analysis

All the cases were reviewed by two experienced radiologists who specialize in breast imaging (F.S. and A.S.). Mammograms were assessed for size and location of FABD, associated clusters of calcifications, presence of a mass or architectural distortion in the examined breast, as well as any change from previous examinations when available (n=42). Sonography was available for 61 of the cases. The patients' medical records were reviewed, and patient age, use of HRT, family history of breast cancer, and presence of a palpable mass were recorded. The patients were divided into two groups according to histological diagnosis. Data for both groups were compared using the unpaired Student's *t*-test.

Results

Five of the 97 biopsied FABD were malignant. Table 1 summarizes the demographic and mammographic data for the women in the benign and malignant groups compared to the whole study cohort.

Clinical data

The average age, calculated area of FABD and prevalence of FABD in the upper outer quadrant were similar for both groups ($P > 0.05$). More women in the group with malignancy presented with a positive family history of breast cancer and the use of HRT than the benign group (40% vs. 23.6% for both parameters, respectively) [Table 1]. FABD were clinically palpable in 60% of the malignant cases and in only 9% of the benign cases. The small size of the group with malignancy precludes our extrapolating the statistical significance of these figures.

Imaging data

The absence of previous mammograms for most of the women in the group with proven malignancy hampers our ability to determine the accuracy of radiological stability as a sign of benignity.

Table 1. Clinical and mammographic data of all patients, including the subgroups of biopsies that were positive and negative for malignancy

	Malignant biopsy (n=5)	Benign biopsy (n=92)	Total (n=97)
Average age (yrs) (range)	56.8 (45–80)	57.4 (35–80)	57.3 (35–80)
Family history of breast cancer	2 (40%)	21 (23.6%)	23 (24.5%)
HRT	2 (40%)	21 (23.6%)	23 (24.5%)
Average use (yrs)	4	5.98	5.8
Upper outer quadrant	3 (60%)	55 (59.8%)	58 (59.8%)
Average area of asymmetry (cm ²) (range)	6.45 (1.2–9.2)	5.71 (0.36–15.75)	5.75 (0.36–15.75)
Previous mammogram			
Not available	4 (80%)	51 (55.4%)	55 (56.7%)
New lesion	1 (20%)	22 (23.9%)	23 (23.7%)
Lesion progression	0 (0%)	9 (9.8%)	9 (9.3%)
Lesion stable	0 (0%)	10 (10.9%)	10 (10.3%)
Cluster of calcification			
No cluster	2 (40%)	81 (88%)	83 (85.6%)
Benign	0 (0%)	11 (12%)	11 (11.3%)
Indeterminate	1 (20%)	0 (0%)	1 (1%)
Possibly malignant	2 (40%)	0 (0%)	2 (2.2%)
Palpable lesion	3 (60%)	8 (9%)	11 (11.7%)

Almost one-quarter (23.9%) of the patients with a benign diagnosis, however, had a new asymmetric density when compared with a previous mammogram [Figure 1A and B]. Architectural distortion was noted in only two cases, and both proved to be malignant on pathological evaluation

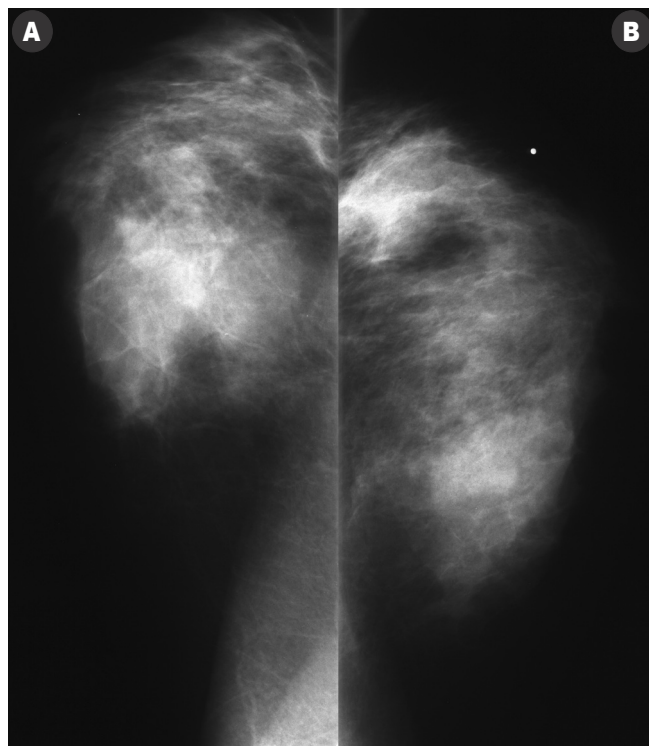


Figure 1. Mediolateral oblique mammogram of the right breast showing a large area of asymmetric density without architectural distortion or calcifications. Pathology revealed focal fibrosis.

Table 2. Summary of pathological findings according to the presence or absence of sonographic findings

Sonography	Pathology
No solid mass (n=55)	Benign (n=53) Normal breast tissue (n=8) Fibrofatty tissue (n=25) Fibrocystic changes (n=16) Pseudoangiomatous changes (n=2) Atypical ductal hyperplasia (n=2) Malignant (n=1) Infiltrating lobular carcinoma (n=1)
Solid mass (n=7)	
Benign ultrasonographic appearance (n=3)	Benign (n=3) Fibrous mastopathy (n=2), Hyalinized fibroadenoma (n=1)
Indeterminate ultrasonographic appearance (n=1)	Benign (n=1) Fibrosis with focal inflammatory infiltrate (n=1)
Malignant ultrasonographic appearance (n=3)	Benign (n=1) Infiltrates of macrophages (n=1) Malignant (n=2) Infiltrating ductal carcinoma (n=1), Infiltrating lobular carcinoma (n=1)

Clusters of calcifications were detected in 60% of the malignant lesions and in only 12% of the benign lesions. None of the benign FABD had indeterminate-type or malignant-type calcifications. Overall, a cluster of calcifications was associated with FABD in 14 of the 97 lesions (14.4%). All 11 cases with a benign-appearing cluster were confirmed pathologically as being benign. Two of the lesions with an associated malignant or suspiciously malignant cluster and one with an indeterminate cluster of calcifications had pathologically proven malignancy.

Sonography was performed in 61 of the 94 patients [Table 2]. No solid mass was identified in the vast majority of patients (88.5%), and only seven masses were detected sonographically. Three of these seven had a benign appearance and were proven pathologically to be benign: fibrous mastopathy (n=2) and fibroadenoma (n=1). Three additional masses had features of a possible malignancy and all were proven on pathology to be malignant. It should also be noted, however, that there were no ultrasound findings in one patient with malignancy (infiltrating lobular carcinoma); this was the only case that was sonographically indeterminate that proved to be false positive. It involved an asymmetric density in a 47 year old patient who had silicone breast implants removed 2 years prior to the index examination. Sonograms showed an ill-defined 1 cm mass not reported on a previous examination (the film itself was not available for direct comparison). Pathology showed an inflammatory infiltrate of macrophages with negative tumor markers and positive macrophage CD-68 on immunohistology, confirming the benign diagnosis.

Discussion

Previous reports have described a wide spectrum of both benign and malignant entities that may be responsible for FABD. Deciding which lesions need further evaluation with core needle

or other biopsy is often clinically challenging. It was suggested that FABD that do not form a mass or are not associated with architectural distortion, clusters of calcification or a clinically palpable mass are most probably a benign variation of the norm and could be safely followed [1,21].

Our study concurs with previous reports that delineate which clinical and mammographic findings are suggestive of a malignant etiology for FABD. Specifically, as Reintgen et al. [21] stated, the presence of a clinically palpable mass was significantly more prevalent in the group of patients with malignancy. The findings of our current study also suggest a relatively high rate of positive family history for breast cancer as well as greater HRT use in cases of malignant FABD, but a larger series is needed to confirm that these factors do indeed increase the likelihood of malignancy.

The radiological findings suggestive of malignant FABD that emerged in our study were architectural distortion, clusters of indeterminate or malignant-appearing calcifications, or the presence of a suspicious mass on ultrasound. The size of FABD was not an indicator for either a benign or malignant outcome. Our literature search yielded two published studies on sonographic findings associated with FABD in a total of 23 patients [2,20]; the results of the prevalence of sonographic findings in these two works were conflicting. In our study of 94 women with 97 FABD, a mass lesion was identified in 7 of 61 sonograms (11.5%), and two of four masses that appeared to be malignant on ultrasound were malignant on pathology as well. There are no sonographic features specific for FABD, another reason that sonography is secondary to mammography. Actually, ultrasound should be used to rule out the diagnoses of other radiographic findings (e.g., whether a solid mass is benign or malignant)

The results of our series led us to conclude that when sonography could not define a lesion, the pathology was benign, and when sonography diagnosed a solid mass the pathology carried a higher probability of malignancy.

Our subgroup of patients with normal ultrasound findings and palpable masses represent Dennis' subgroup of patients who do not need a biopsy [22]. We believe that a biopsy is absolutely necessary in all cases when asymmetry is detected on imaging in the presence of a palpable mass. We agree with the approach that palpable asymmetric density seen for the first time on mammography with normal ultrasound, in spite of the low risk of malignancy, should be biopsied. On the other hand, asymmetric density whose appearance is stable on mammography over the years should not be biopsied. Dennis et al. [22] suggested that biopsy should be avoided in cases of palpable masses with normal mammographic findings, but we believe that some malignancies can be missed if this approach is followed.

The major limitation of this study is its retrospective nature. An additional limitation may be bias in patient selection since we included FABD that had associated radiological findings suggestive of malignancy. We chose to include all FABD cases that were seen during the study period in order to quantify the frequency of the findings associated with it; in clinical practice, any architectural distortion or malignant-appearing calcifications

would, of course, mandate a biopsy with or without concomitant FABD. Nonetheless, none of the lesions that had an associated cluster of calcifications or a mass that appeared to be benign on ultrasound were malignant. Therefore, it seems reasonable to conclude that when calcifications are associated with FABD, or when a mass is seen on the ultrasonogram, the level of suspicion of a malignant lesion is determined by the associated finding(s) and not by the parenchymal density. If we omit the five lesions that would have been biopsied regardless of FABD, e.g., the presence of suspicious or indeterminate calcifications, architectural distortion or a sonographically suspicious mass, it emerges that only one of the 92 remaining lesions (1.1%) was malignant.

Almost one-half of our patients had previous mammograms that were available for comparison. Since over one-third of the benign group had a new or growing FABD, those findings clearly do not testify to a malignant condition. Previous studies, however, have shown that new or growing FABD should be managed with caution [23]. Due to the small number of malignant lesions and lack of previous mammograms in most of them, we cannot assess the overall probability of malignancy growing or new FABD from our data.

In conclusion, FABD in the absence of architectural distortion, cluster of malignant-appearing or indeterminate calcifications, a sonographically suspicious mass or a clinically palpable mass can be safely managed by follow-up without biopsy. The presence of any one of those findings, however, mandates further diagnostic evaluation for malignancy.

Acknowledgment. Esther Eshkol is thanked for editorial assistance.

References

- American College of Radiology. Breast imaging reporting and data system (BI-RADS). 2nd edn. Reston, VA: American College of Radiology, 1995.
- Piccoli CW, Feig SA, Palazzo JP. Developing asymmetric breast tissue. *Radiology* 1999;211:111–17.
- Hall JA, Murphy DC, Hall BR, Hall KA. Mammographic abnormalities and the detection of carcinoma of the breast. *Am J Obstet Gynecol* 1993;168:1677–82.
- Knutzen AM, Gisvold JJ. Likelihood of malignant disease for various categories of mammographically detected nonpalpable breast lesions. *Mayo Clin Proc* 1993;68:454–60.
- Jeffries DO, Adler DD. Mammographic detection of breast cancer in women under the age of 35. *Invest Radiol* 1990;25:67–71.
- Skinner MA, Swain M, Simmons R, McCarty KS Jr, Sullivan DC, Iglehart JD. Nonpalpable breast lesions at biopsy. A detailed analysis of radiographic features. *Ann Surg* 1988;208:203–8.
- Dawson JS, Wilson AR. Short-term recall for “probably benign” mammographic lesions detected in a three yearly screening programme. *Clin Radiol* 1994;49:391–5.
- Goedde TA, Fryberg ER, Crump JM, Lay SF, Turetsky DB, Linden SS. The impact of mammography on breast biopsy. *Am Surg* 1992;58:661–6.
- Skaane P, Skjorten F. Ultrasonographic evaluation of invasive lobular carcinoma. *Acta Radiol* 1999;40:369–75.
- Goodman DN, Boutross-Tadross O, Jong RA. Mammographic features of pure mucinous carcinoma of the breast with pathological correlation. *Can Assoc Radiol J* 1995;46:296–301.
- Elson BC, Helvie MA, Frank TS, Wilson TE, Adler DD. Tubular carcinoma of the breast: mode of presentation, mammographic appearance and frequency of nodal metastases. *Am J Roentgenol* 1993;161:1173–6.
- Sung DW, Lim JW, Yoon Y, Kim YW, Lee JH, Cho KS. Primary breast lymphoma. *J Korean Med Sci* 1993;8:210–13.
- Crowe DJ, Helvie MA, Wilson TE. Breast infection: mammographic and sonographic findings with clinical correlation. *Invest Radiol* 1995;30:582–7.
- Oh KK, Kim JH, Kook SH. Imaging of tuberculous disease involving breast. *Eur Radiol* 1998;8:1475–80.
- Venta LA, Wiley EL, Gabriel H, Adler YT. Imaging features of focal breast fibrosis: mammographic-pathologic correlation of noncalcified breast lesions. *Am J Roentgenol* 1999;173:309–16.
- Poulton TB, de Paredes ES, Baldwin M. Sclerosing lobular hyperplasia of the breast: imaging features in 15 cases. *Am J Roentgenol* 1995;165:291–4.
- Zonderland HM, Michiels JJ, ten Kate FJ. Case report: mammographic and sonographic demonstration of extramedullary haematopoiesis of the breast. *Clin Radiol* 1991;44:64–5.
- Cyrlak D, Wong CH. Mammographic changes in postmenopausal women undergoing hormonal replacement therapy. *Am J Roentgenol* 1993;161:1177–83.
- Stomper PC, Van Voorhis BJ, Ravnkar VA, Meyer JE. Mammographic changes associated with postmenopausal hormone replacement therapy: a longitudinal study. *Radiology* 1990;174:487–90.
- Rissanen, Pamilo M, Suramo I. Ultrasonography as a guidance method in the evaluation of mammographically detected nonpalpable breast lesions of suspected malignancy. *Acta Radiol* 1998;39:292–7.
- Reintgen D, Berman C, Cox C, et al. The anatomy of missed breast cancers. *Surg Oncol* 1993;2:65–75.
- Dennis MA, Parker SH, Klaus AJ, Stavros AT, Kaske TI, Clark SB. Breast biopsy avoidance: the value of normal mammograms and normal sonograms in the setting of a palpable lump. *Radiology* 2001;219:186–91.
- Leung JW, Sickles EA. Developing asymmetry identified on mammography: correlation with imaging outcome and pathologic findings. *Am J Roentgenol* 2007;188:667–75.

Correspondence: Dr. N. Yaal-Hahoshen, Dept. of Oncology, Tel Aviv Sourasky Medical Center, 6 Weizmann Street, Tel Aviv 64239, Israel.
Phone: (972-3) 697-3413
Fax: (972-3) 697-4828
email: neora@tasmc.health.gov.il

Anything you lose automatically doubles in value

Mignon McLaughlin (1915-1983), American journalist and author