

Our Experience with a "Homemade" Vacuum-Assisted Closure System

Avshalom Shalom MD, Hadad Eran MD, Melvyn Westreich MD and Tal Friedman MD

Department of Plastic Surgery, Assaf Harofeh Medical Center, Zerifin, and Sackler Faculty of Medicine, Tel Aviv University, Ramat Aviv, Israel

Key words: negative pressure, dressing, cost-effective, improvised

Abstract

Background: Negative-pressure therapy for the closure of wounds, a technique to accelerate secondary wound healing, is clinically available as the V.A.C.™ system (KCI Inc, San Antonio, TX, USA). Budgetary considerations in our institution precluded widespread use of the expensive V.A.C.™ system in routine cases.

Objectives: To develop a less expensive comparably effective dressing, based on the same principles.

Methods: We used our "homemade" system to treat 15 patients with appropriate complex wounds. Their hospital charts were reviewed and assessed retrospectively. Cost analysis was performed comparing our dressing with the V.A.C.™ system.

Results: Our homemade negative-pressure wound treatment system obtained results similar to what one could expect with the V.A.C.™ system in all parameters. Complications encountered were few and minor. Cost per day using our negative-pressure system for a 10 cm² wound is about US\$1, as compared to US\$22, utilizing the V.A.C.™ system.

Conclusions: Our homemade negative-pressure system proved to be a good cost-effective treatment for wound closure in hospitalized patients, yielding results comparable to those of the more expensive V.A.C.™ system.

IMAJ 2008;10:613-616

Negative-pressure therapy was first described in 1989 (unpublished data, Kinetic Concepts Inc., at scientific meetings) and has been commercially available in the United States since 1995 as a technique to accelerate secondary wound healing in postoperative patients [1,2]. The V.A.C.™ wound closure system (KCI Inc, San Antonio, TX) was first presented in the literature by Argenta and Moryk in 1997 [1]. Many studies thereafter extensively described its properties in animal models and clinical studies [1-7]. Two broad mechanisms of action of negative pressure therapy were proposed: removal of fluids and mechanical deformation [8]. Fluid removal encompasses two beneficial effects in the process of wound healing. The first is a decrease in edema, leading to a decrease in interstitial pressure and a reduction in diffusion distance [8]. The second is the removal of soluble factors such as cytokines, collagenases and elastases, which are primary inhibitors of fibroblasts and endothelial cell proliferation – essential to proper wound healing [1]. The relationship between mechanical deformation and increased growth is well known, as it is the basis of tissue expansion [9]. An altered wound environment promotes increased blood flow and oxygen tension [10], decreased bacterial counts [11] and increased granulation tissue formation [12], resulting in improved wound healing [1,2].

The high cost of the V.A.C.™ system led to the need to develop a less expensive comparably effective dressing, based on the same principles. A much cheaper commercial V.A.C.-like device is now available (Blue Sky Medical, USA). In our institution for the past 3 years we have also regularly utilized a cheaper comparably effective dressing, based on the same principles.

Patients and Methods

All patients with complex wounds treated with our improvised vacuum-assisted closure system over the past year (December 2002 to December 2003) were assessed retrospectively, and their hospital charts were reviewed. The data collected included age and medical status of the patients, wound type and location, length of treatment applied, and frequency of dressing change. Local and systemic complications were also noted. We calculated the cost per day of treatment with our dressing, and compared it to that of the V.A.C.™ System.

Technique

The clean open wound is covered with one layer of Jelonet, and a sterile polyvinyl-alcohol sponge, slightly smaller in diameter than the wound itself, is then placed over the Jelonet [Figure 1]. A wide-caliber evacuation tube is placed above the sponge, after making a few holes at the distal end with scissors [Figure 2]. A second sponge layer then covers the tube, and the whole area is sealed with adhesive drape (Steri-Drape, 3M, USA) extending approximately 5 cm beyond the margins of the wound, thus creating an airtight seal [Figure 3]. The proximal end of the tube is

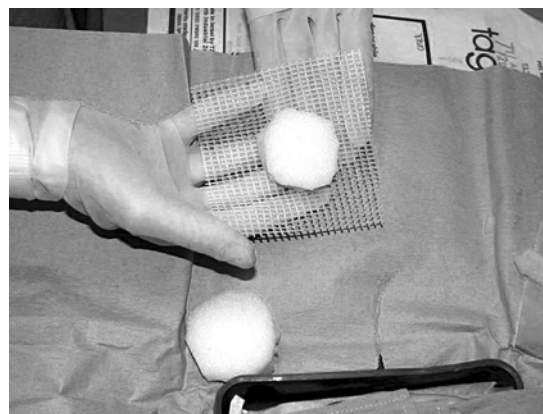


Figure 1. Sterile sponge, wrapped in a layer of Jelonet, is placed over the open wound.

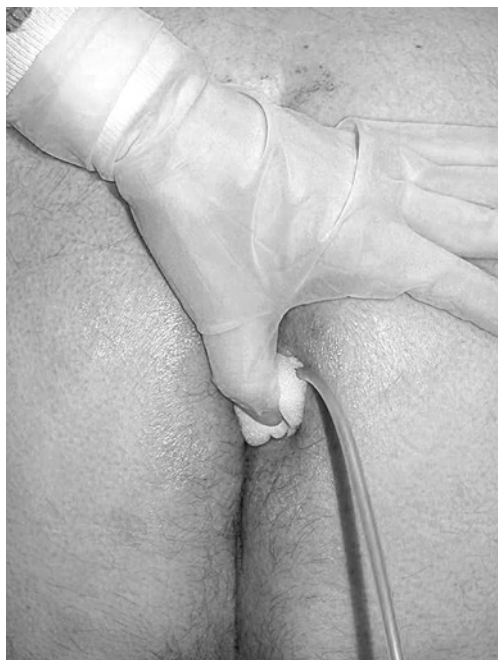

Figure 2. Evacuation tube is placed over the sponge, and covered with a second sponge layer.

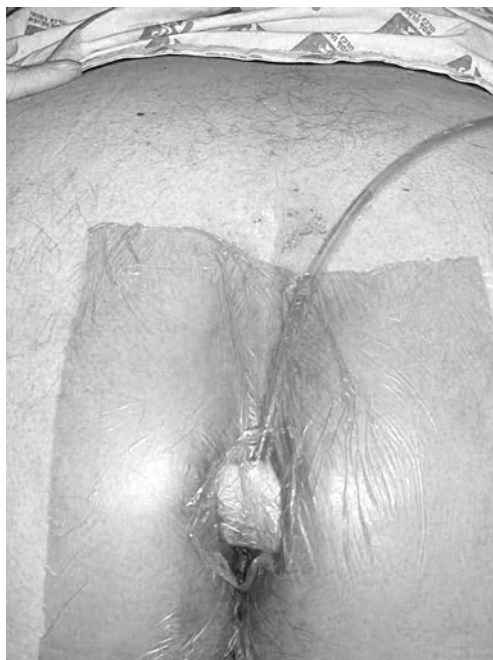

Figure 3. The whole area is covered with adhesive drape, creating an airtight seal.

to 31 days (mean length 22 days). Negative pressure treatment ranged from 2 to 30 days (mean of almost 12 days).

All wounds responded favorably to the application of the negative-pressure dressing. One patient with huge neglected chronic leg ulcers was suspected of having local wound cellulites while the closed dressing was applied, and the improvised vacuum-assisted closure treatment was therefore suspended for a few days. Odor was a second problem during the treatment of this patient. Another patient had dermatitis around the wound margins. This may be attributed to the Steri-Drape, a total occlusive dressing that can cause

an accumulation of moisture when used for long periods. As such, we decreased the Steri-Drape wound-free margins and added steroid ointment, which relieved the dermatitis. In order to avoid local skin problems, transparent films with semi-occlusive properties, such as Tegaderm (3M, USA) and Opsite (Smith and Nephew, UK) may be used. These allow moisture evaporation and are designed to remain on the skin for several days. Other known local complications, such as excessive ingrowth of granulation tissue or erosions of margins, were not identified in our patients. Therapy was continued until the wound was ready for skin grafting (five patients), or decreased significantly allowing for delayed primary intention (three patients), or for a shorter period of secondary healing (seven patients).

Results

During the last year 15 patients (10 females and five males) who ranged in aged from 22 to 83 years (median age 59.3 years) with subacute and chronic wounds were treated with this system.

Subacute wounds

Eight patients had open wounds for less than 7 days: three patients had dehiscence wounds in the distal margins of the abdominal flap after a transverse rectus abdominus muscle flap procedure (two patients), and abdominoplasty (one patient); one patient had an ankle defect due to a necrotic traumatic flap; one patient had an open necrotic wound of one breast; and three patients had a lower extremity open wound following a recent hematoma evacuation.

Chronic wounds

Seven patients had open wounds for longer than 4 weeks: five patients had venous stasis ulcers of the legs, one patient had a radiation ulcer, and one had a vasculitic ulcer. Initial treatment consisted of surgical debridement of all non-viable tissue, if needed. Sub-atmospheric pressure was applied in a continuous mode for 24–48 hour periods, and the wound was then reassessed for subsequent closure. When changes in local wound discharge were recognized, chlorosept wet-gauze dressings were usually used for a few hours a day, and then treatment with the vacuum system was resumed. Length of hospitalization ranged from 10

The cost of the negative-pressure dressing components is detailed in Table 1. The suction tube costs \$0.1; one sponge, at a cost of \$1.38, is sufficient for 25 wounds with a surface area of 10 cm² (therefore the two pieces needed for each wound cost \$0.05); one Steri-Drape costing \$4.33 is sufficient to cover two to three wounds, which means \$2.16 maximum per wound; one unit of Jelonet costs \$0.31. Therefore, the cost of one dressing change for a 10 cm² open wound is \$2.7 and the cost per treatment day using our negative-pressure system is \$1.35 when the dressing is changed once every 2 days [Table 1], as compared to \$80 when utilizing the V.A.C.TM System (KCI, Inc, San Antonio, TX) at the patient's home, or \$22 during hospitalization, utilizing existing acquired devices (the price of which is \$7000–9000).

Discussion

In this era of economically based medicine, cheaper treatment modalities must be sought. We designed a negative-pressure dress-

Table 1. Cost of the dressings

Component	Cost
Suction tube	\$0.16
Sponge (0.5 x 1 m)	\$1.38
2 Sponge (10 x 10 cm)	\$0.05
Steri-Drape (60 x 45 cm)	\$4.33
Steri-Drape (20 x 20 cm)	\$2.16
Jelonet (10 x 10 cm)	\$0.31
Cost of V.A.C.™ System (KCI, Inc, San Antonio, TX)	
During hospitalization	\$22 (per day)
Cost of a device	\$7000–9000

ing for a wide range of wounds with the aim of increasing patient comfort, decreasing length of hospitalization stay and decreasing costs. We were aware of specific warnings mentioned by Argenta et al. [1], who discouraged the use of large controlled vacuums such as a wall suction, which might induce wound desiccation due to large volumes of air. The desiccation phenomenon did not occur in any of our patients, probably as a result of the completely tight seal and meticulous pressure monitoring. In addition, we used regular closed-cell foam rather than open-cell foam. All regions of the wound surface area responded similarly, with no compromised regions. The application of a cheaper sponge, compared to the specific semi-open one applied with the V.A.C.™ system, did not seem to make any difference to third-space fluid removal.

Eleven wounds responded dramatically to treatment, with rapid removal of the edema surrounding the chronic wounds, significant decrease in wound size, and enhanced granulation tissue formation. With frequent evaluations of the wound, the complications were scarce.

A review of the literature regarding "homemade" wall suction for treating wounds revealed a few relevant publications. Fenn and Butler [13] combined foam suction dressing with rapid serial wound closure in four patients with abdominoplasty wound dehiscence. They achieved effective delayed primary closure of the abdominoplasty wound within 8 days with an acceptable aesthetic result. According to them, the combination of an occlusive dressing and the foam yields several benefits. First, it is a closed absorbent dressing system, with the wound effluent being effectively evacuated by the suction system. Second, the suction system eliminates the dead space under the abdominal flap. Finally, the transparent occlusive dressing enables inspection of the wound edges without disturbing the dressing. A disadvantage of this approach is the need for administering multiple general anesthetics [13]. Philbeck et al. [14] evaluated 1170 pressure ulcers and other chronic wounds that failed to respond to previous interventions and were subsequently treated at home with negative pressure wound therapy. Reductions in wound area and volume were compared and costs analyzed. The average 22.2 cm² wound treated with conventional therapy would take 247 days to heal and cost \$23,465. Using negative-pressure wound therapy the wound would heal in 97 days and cost \$14,546. The study concluded that negative-pressure wound therapy is an

efficacious and economical treatment modality for a variety of chronic wounds [14]. The healing rate of pressure ulcers treated by this modality is 61% faster and costs 38% less. Fleischmann and colleagues [15] also showed their beneficial results with "homemade" vacuum sealing in 121 patients with traumatic soft tissue defects.

The main drawback of the method described in the present paper is that it cannot be used outside a hospital or other institutions that have a wall suction. Many patients are discharged home with the V.A.C.™ machine after a few days of hospitalization and they can even ambulate with it. Treatment at home is much cheaper (one-fifth of the cost) and more economical than keeping patients in hospital. Therefore, the cost-effectiveness of the "homemade" vacuum-assisted closure system is limited to hospitalized patients. Another drawback of the homemade vacuum system is death from uncontrolled excessive bleeding into the vacuum tubing, an air leak that dries the wound and worsens its condition [10], and an uncontrolled vacuum that can harm the wound surface and cause infection. Many reports claim good results with the homemade vacuum device, but the dangers associated with its use should be addressed.

Conclusions

Based on these results, we believe that that this homemade negative-pressure system is a good cost-effective treatment for wound closure in hospitalized patients, yielding comparable results to the more expensive V.A.C.™ system.

References

1. Argenta LC, Morykwas MJ. Vacuum-assisted closure: a new method for wound control and treatment: clinical experience. *Ann Plast Surg* 1997;38:563–76.
2. Morykwas MJ, Argenta LC, Shelton-Brown EI, McGuirt W. Vacuum-assisted closure: a new method for wound control and treatment: animal studies and basic foundation. *Ann Plast Surg* 1997;38:553–62.
3. Blackburn JH 2nd, Boemi L, Hall WW, et al. Negative-pressure dressings as a bolster for skin grafts. *Ann Plast Surg* 1998;40:453–7.
4. DeFranzo AJ, Marks MW, Argenta LC, Genecov DG. Vacuum-assisted closure for the treatment of degloving injuries. *Plast Reconstr Surg* 1999;104:2145–8.
5. Greer SE, Longaker MT, Margiotta M, Mathews AJ, Kasabian A. The use of subatmospheric pressure dressing for the coverage of radial forearm free flap donor-site exposed tendon complications. *Ann Plast Surg* 1999;43:551–4.
6. Hallberg H, Holmstrom H. Vaginal construction with skin grafts and vacuum-assisted closure. *Scand J Plast Reconstr Surg Hand Surg* 2003;37:97–101.
7. Mooney JF 3rd, Argenta LC, Marks MW, Morykwas MJ, DeFranzo AJ. Treatment of soft tissue defects in pediatric patients using the V.A.C.™ system. *Clin Orthop Relat Res* 2000;376:26–31.
8. Morykwas MJ, Simpson J, Pungler K, Argenta A, Kremers L, Argenta J. Vacuum-assisted closure: state of basic research and physiologic foundation. *Plast Reconstr Surg* 2006;117(7 Suppl):121–6S.
9. Saxena V, Hwang CW, Huang S, Eichbaum Q, Ingber D, Orgill DP. Vacuum-assisted closure: microdeformations of wounds and cell proliferation. *Plast Reconstr Surg* 2004;114:1086–96.

Original Articles

10. Chen SZ, Li J, Li XY, Xu LS. Effects of vacuum-assisted closure on wound microcirculation: an experimental study. *Asian J Surg* 2005;28:211–17.
11. Mouës CM, Vos MC, van den Bemd GJ, Stijnen T, Hovius SE. Bacterial load in relation to vacuum-assisted closure wound therapy: a prospective randomized trial. *Wound Repair Regen* 2004;12:11–17.
12. Morykwas MJ, Faler BJ, Pearce DJ, Argenta LC. Effects of varying levels of subatmospheric pressure on the rate of granulation tissue formation in experimental wounds in swine. *Ann Plast Surg* 2001;47:547–51.
13. Fenn CH, Butler PE. Abdominoplasty wound-healing complications: assisted closure using foam suction dressing. *Br J Plast Surg* 2001;54:348–51.
14. Philbeck TE Jr, Whittington KT, Millsap MH, Briones RB, Wight DG, Schroeder WJ. The clinical and cost effectiveness of externally applied negative pressure wound therapy in the treatment of wounds in home healthcare Medicare patients. *Ostomy Wound Manage* 1999;45:41–50.
15. Fleischmann W, Becker U, Bischoff M, Hoekstra H. Vacuum sealing: indication, technique, and results. *Eur J Orthop Surg Traumatol* 1995;5:37–40.

Correspondence: Dr. T. Friedman, Dept. of Plastic Surgery, Assaf Harofeh Medical Center, Zerifin 70300, Israel.
Phone: (972-8) 977-9416; Fax: (972-8) 977-9427
email: fredricag@asaf.health.gov.il