

Why the Real-Life Diagnosis of Non-Radiographic Axial Spondyloarthritis Is So Difficult

Gleb Slobodin MD

Rheumatology Unit, Bnai Zion Medical Center, affiliated with Rappaport Faculty of Medicine, Technion–Israel Institute of Technology, Haifa, Israel

KEY WORDS: ankylosing spondylitis (AS), classification criteria, non-radiographic axial spondyloarthritis (nr-AxSpA), sacroiliitis, spondyloarthritis (SpA)

IMAJ 2020; 22: 390–392

The entity of non-radiographic axial spondyloarthritis (nr-AxSpA) has been formally accepted by the medical community for more than a decade. Dozens of studies on the clinical manifestations, treatment, and prognosis of nr-AxSpA have been published and widely discussed. Thousands of patients are followed in the established nr-AxSpA cohorts all over the world. Still, significant disagreements on the diagnosis of nr-AxSpA in the daily rheumatology practice exist and even deepen with time. The absence of the diagnostic criteria for nr-AxSpA should not be blamed, as rheumatologists are used to diagnosing and treating conditions with no available diagnostic criteria. However, no other rheumatic disease has caused so many controversies and misunderstandings in recent times. The goal of this article was to comprehend and analyze the difficulties in diagnosing nr-AxSpA.

Essence of nr-AxSpA

The insensitivity of the existing 1984 modified New York criteria for the early stage of ankylosing spondylitis (AS) and hope that newly available biologic therapies would prevent disease-related distress and damage have led to the creation of Assessment of SpondyloAr-

thritis international Society (ASAS) classification criteria for axial spondyloarthritis, published in 2009 [1,2]. However, the definition of nr-AxSpA in the core study was not limited to early AS without radiographic sacroiliitis, but instead included all spondyloarthritis (SpA) with predominantly axial involvement but without definite radiographic sacroiliitis [1]. Thus, the original term of nr-AxSpA contains a broad spectrum of conditions beyond early AS. These include psoriatic spondylitis or spondylitis related to inflammatory bowel disease, reactive arthritis, and undifferentiated SpA [3]. In other words, the term nr-AxSpA was suggested as an all encompassing name for a subgroup of disorders within the SpA group to understand better the mechanisms and evolution of axial involvement and, hopefully, to learn how to differentiate pre-radiographic AS from the other nr-AxSpA associates. Current data show that 4–10% of patients classified with nr-AxSpA develop features of AS every 2 years [4,5]. A simple calculation based on a 2% per year number leads to a conclusion that 50% of the nr-AxSpA patients will progress to AS within 35 years ($\log(1/2)/\log 0.98+1 \approx 35$). In other words, a very sensible percentage of individuals marked as having nr-AxSpA, are not expected to develop radiographic sacroiliitis during their life course. Who will progress to AS and how to recognize these patients early and prevent damage represent some of the research questions.

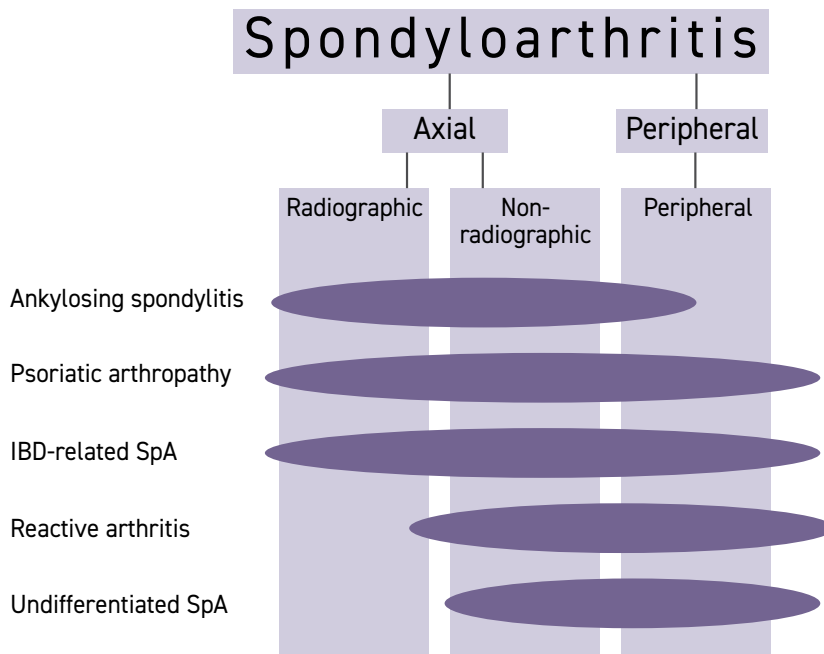
Thus, the basic meaning of nr-AxSpA is not a new disease to be diagnosed in clinical practice, but rather a substrate for research, a subgroup of SpA [Figure 1].

Prior and current approach to the diagnosis of pre-radiographic AS

The understanding that AS is a continuity and that the disease does not necessarily manifest with apparent sacroiliitis, particularly in the early disease stages, had found its expression in the Rome 1961 clinical criteria for ankylosing spondylitis [Table 1] [6]. By these criteria, AS could be diagnosed in the presence of a combination of clinical manifestations, with no evidence of sacroiliitis on imaging. While far from perfect, the Rome criteria allowed the diagnosis of early disease as well as acknowledged the AS diversity. The research, however, demanded stricter standards to form more homogenous cohorts, and 1966 and 1984 modified New York criteria made a drastic change in the whole approach to the diagnosis of AS: the imaging data were given diagnostic priority over clinical judgment. Now, the disease could be diagnosed only in the presence of radiographic sacroiliitis. Probable AS could be considered in individuals with all clinical criteria present but no sacroiliitis on imaging [7]. Eventually, acknowledgement of the probable AS disappeared from this criteria set [8].

The New York criteria advanced the research in the field of AS but have led to at least two negative consequences. First, these classification criteria started being used in clinical practice for routine diagnosis, and the vast majority of early AS patients with still normal radiograms were denied a diagnosis of AS until sacroiliitis could be detected.

Figure 1. The original position of nr-AxSpA in the SpA group
 nr-AxSpA = non-radiographic axial spondyloarthritis, IBD = inflammatory bowel disease, SpA = spondyloarthritis



The resulting from such an approach delay in AS diagnosis reached a remarkable value of about 10 years [9]. Second, the rule of ‘imaging first’ in the diagnosis of AS has deeply infiltrated the clinical practice and still frequently overcomes the clinical judgment, no matter whether radiography, magnetic resonance (MRI), or computed tomography is utilized.

In recent years, pre-radiographic AS began to be widely equated with nr-AxSpA for the clinical purposes, and the term of AxSpA has become a roof name for both pre-radiographic and classic AS [10].

Risks of using the ASAS classification criteria for AxSpA for diagnostic (vs. classification) purposes

The concept that nr-AxSpA represents an early AS and can be diagnosed as such using the existing ASAS classification criteria can look attractive in the management of some problematic patients in

rheumatology practice. However, ASAS classification criteria have never been validated as a diagnostic tool. Moreover, repeated calls have been published against the use of these criteria for routine diagnosis [11,12]. Nevertheless, the ease of using ‘positive’ MRI of sacroiliac joints as a cornerstone of the diagnosis of nr-AxSpA, analogous to the widely accepted role of radiographic sacroiliitis in the diagnosis of AS can be appealing. Cases in which a patient with apparent fibromyalgia is referred for the MRI of sacroiliac joints not to miss nr-AxSpA are not rare, and some of these patients start endless rounds of expensive and useless biologic treatments. It should be noted that 97% specificity of MRI findings for the diagnosis of nr-AxSpA was shown in patients already diagnosed with SpA by experts [1,2]. Thus, MRI can be an outstanding diagnostic tool in a patient who has a clinical profile of SpA and needs further investigation to secure the diagnosis. However, it has been unequiv-

ocally demonstrated that “positive” MRI of the sacroiliac joints is frequently seen in athletes, individuals with non-specific back pain, and healthy volunteers, making it entirely inappropriate for the diagnosis of nr-AxSpA in individuals without clinical features of SpA [13-15].

The principle of ‘clinical judgment first’ has to come back to avoid the over-diagnosis of nr-AxSpA in routine clinical practice. In addition, using the ASAS classification criteria for the diagnosis of nr-AxSpA will miss lots of patients, starting with those older than 45 years old or others with convincing clinical presentation, but inconclusive MRI, for example. Also, HLA B27, having a different prevalence in various populations, is expected to bear variable impact as well, if used for diagnostic purposes. Thus, the ASAS classification criteria should be used for classification and research purposes only, securing the homogenous patients cohorts and not for the diagnosis in clinical practice. Early clinical diagnosis of AxSpA,

Table 1. The Rome (1961) clinical criteria for AS. The diagnosis could be made when bilateral sacroiliitis and one of five clinical criteria are present, or when four clinical criteria are present

Clinical criteria	
1.	Low back pain and stiffness > 3 months, not relieved by rest
2.	Pain and stiffness in the thoracic region
3.	Limited motion in the lumbar spine
4.	Limited chest expansion
5.	History or evidence of iritis
Radiological criterion	
6.	Bilateral sacroiliitis

including pre-radiographic AS, should be based instead on clinical judgment and the scientific probability of findings, for example, using the approach suggested more than a decade ago [16].

Conclusions

The entity of nr-AxSpA has received partly differential meaning for research and clinical practice. The ASAS classification criteria for axial spondyloarthritis are widely used for the selection of patients suitable for research, but are not recommended for use in the diagnostic purposes. Practicing rheumatologists equating the nr-AxSpA with pre-radiographic AS should diagnose this condition based on clinical judgment and experience, as they have been doing for decades concerning many other rheumatic diseases, which do not have available diagnostic criteria.

Capsule

Safe vaccine development

The coronavirus disease 2019 (COVID-19) pandemic has prompted accelerated vaccine development in the hope that predicted mortality rates can be reduced and population, or herd, immunity achieved. These measures could result in eventual eradication of the disease. In a perspective, **Graham** discussed the need to ensure that

vaccines are safe and do not aggravate coronavirus infection. Based on lessons learned from past vaccines, various steps need to be taken to ensure that expedited vaccine development is accompanied in parallel by safety assessments to prioritize the most effective candidates.

Science 2020; 368: 945

Correspondence

Dr. G. Slobodin
 Rheumatology Unit, Bnai Zion Medical Center, Haifa 38041, Israel
Phone: (972-4) 835-9997
Fax: (972-4) 837-2898
email: gslobodin@yahoo.com

References

- Rudwaleit M, Landewé R, van der Heijde D, et al. The development of Assessment of SpondyloArthritis international Society classification criteria for axial spondyloarthritis (part I): classification of paper patients by expert opinion including uncertainty appraisal. *Ann Rheum Dis* 2009; 68 (6): 770-6.
- Rudwaleit M, van der Heijde D, Landewé R, et al. The development of Assessment of SpondyloArthritis international Society classification criteria for axial spondyloarthritis (part II): validation and final selection [published correction appears in *Ann Rheum Dis* 2019; 78 (6): e59]. *Ann Rheum Dis* 2009; 68 (6): 777-83.
- Akkoc N, Khan MA. ASAS classification criteria for axial spondyloarthritis: time to modify. *Clin Rheumatol* 2016; 35 (6): 1415-23.
- Poddubny D, Rudwaleit M, Haibel H, et al. Rates and predictors of radiographic sacroiliitis progression over 2 years in patients with axial

spondyloarthritis. *Ann Rheum Dis* 2011; 70 (8): 1369-74.

- Wang R, Gabriel SE, Ward MM. Progression of nonradiographic axial spondyloarthritis to ankylosing spondylitis: a population-based cohort study. *Arthritis Rheumatol* 2016; 68 (6): 1415-21.
- Moll JM, Wright V. New York clinical criteria for ankylosing spondylitis. A statistical evaluation. *Ann Rheum Dis* 1973; 32 (4): 354-63.
- van der Linden S, Valkenburg HA, Cats A. Evaluation of diagnostic criteria for ankylosing spondylitis. A proposal for modification of the New York criteria. *Arthritis Rheum* 1984; 27 (4): 361-8.
- Rudwaleit M. Classification and epidemiology of spondyloarthritis. In *Rheumatology*, 7th Edition, Philadelphia: Elsevier, 2019: 993-7.
- Feldtkeller E, Khan MA, van der Heijde D, van der Linden S, Braun J. Age at disease onset and diagnosis delay in HLA-B27 negative vs. positive patients with ankylosing spondylitis. *Rheumatol Int* 2003; 23 (2): 61-6.
- Deodhar A, Strand V, Kay J, Braun J. The term 'non-radiographic axial spondyloarthritis' is much more important to classify than to diagnose patients with axial spondyloarthritis. *Ann Rheum Dis* 2016; 75 (5): 791-4.
- Deodhar A. Axial spondyloarthritis criteria and modified NY criteria: issues and controversies. *Clin Rheumatol* 2014; 33 (6): 741-7.
- June RR, Aggarwal R. The use and abuse of diagnostic/classification criteria. *Best Pract Res Clin Rheumatol* 2014; 28 (6): 921-34.
- Cédric Lukas, Catherine Cyteval, Maxime Dougados, Ulrich Weber. MRI for diagnosis of axial spondyloarthritis: major advance with critical limitations 'Not everything that glisters is gold (standard)'. *RMD Open* 2018; 4 (1): e000586.
- Weber U, Jurik AG, Zejden A, et al. Frequency and anatomic distribution of magnetic resonance imaging features in the sacroiliac joints of young athletes: exploring "background noise" toward a data-driven definition of sacroiliitis in early spondyloarthritis. *Arthritis Rheumatol* 2018; 70 (5): 736-45.
- Baraliakos X, Richter A, Feldmann D, Ott A, Buelow R, Schmidt CO, Braun J. Frequency of MRI changes suggestive of axial spondyloarthritis in the axial skeleton in a large population-based cohort of individuals aged <45 years. *Ann Rheum Dis* 2020; 79 (2): 186-92.
- Rudwaleit M, van der Heijde D, Khan MA, Braun J, Sieper J. How to diagnose axial spondyloarthritis early. *Ann Rheum Dis* 2004; 63 (5): 535-43.