

Yellow Nail Syndrome

Emily Avitan-Hersh MD DSc¹, Gidon Berger MD² and Reuven Bergman MD^{1,3}

¹Department of Dermatology and ²Pulmonology Division, Rambam Health Care Campus, Haifa, Israel

³Rappaport Faculty of Medicine, Technion-Israel Institute of Technology, Haifa, Israel

KEY WORDS: yellow nail syndrome, vascular malformation, D2-40, CD31, vascular endothelial growth factor receptor-3 (VEGFR-3), von Willebrand factor

IMAJ 2011; 13: 577–578

Yellow nail syndrome is a rare syndrome characterized by slow-growing, over-curved yellow nails, bilateral leg lymphedema and lung abnormalities including pleural effusion and bronchiectasis. Other manifestations may include recurrent sinusitis, recurrent respiratory tract infections, pericardial effusion and ocular abnormalities. Since its first description in 1964 [1], the pathogenesis and genetic basis of this syndrome have not been established. We present a case of yellow nail syndrome in which the abnormal dilated vessels in the lymphedematous skin stained positively for D2-40 antibody and vascular endothelial growth factor receptor-3, considered to

be markers for lymphatic endothelial cells [2,3], and for CD31 and von Willebrand factor, considered to be markers of vascular endothelial cells [4].

PATIENT DESCRIPTION

A 40 year old man, the son of non-consanguineous healthy parents of Arab extraction, was hospitalized in our department because of left leg cellulitis. His medical history included bronchiectasis complicated by recurrent respiratory tract infections that necessitated lobectomy at age 20. Since adolescence he had suffered from swollen feet with recurrent leg cellulitis. The patient also displayed recurrent sinusitis. He had never smoked and there was no history of tuberculosis. Similar abnormalities were not reported in his family.

Physical examination revealed bilateral lymphedema of both legs and toes, which were covered by thick verrucous skin. The toenails were yellow, over-curved, dystrophic, thick and without

a cuticle [Figure A]. Chest auscultation demonstrated bilateral, scattered, coarse crackles in the lower lobes.

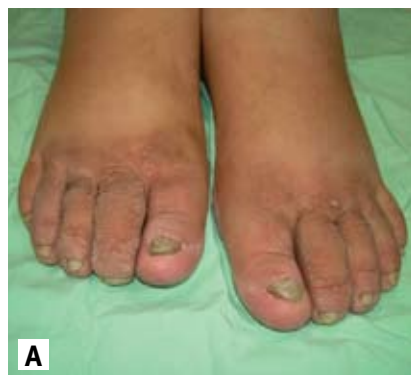The routine laboratory studies demonstrated normal liver and renal function tests, normal albumin levels and no proteinuria. Repeated mycological cultures obtained from the involved nails were negative. Pulmonary spirometry revealed moderate limitation of the airflow.

High-resolution computed tomography scan of the chest showed postoperative changes in the left lower lobe, and mild cylindrical bronchiectasis, mainly in the right lower lobe with sub-segmental atelectasis in the right middle lobe and lingula. Small amounts of pericardial effusion were also seen.

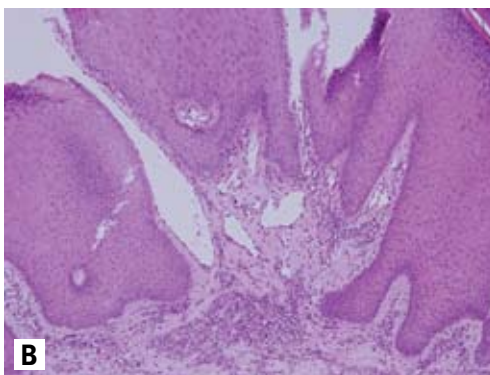
HISTOPATHOLOGY AND IMMUNOHISTOCHEMISTRY

The histological examination of the skin biopsy obtained from the lymphedematous leg showed marked acanthosis and papillomatosis of the epidermis [Figure B]. Multiple dilated vessels lined by thin

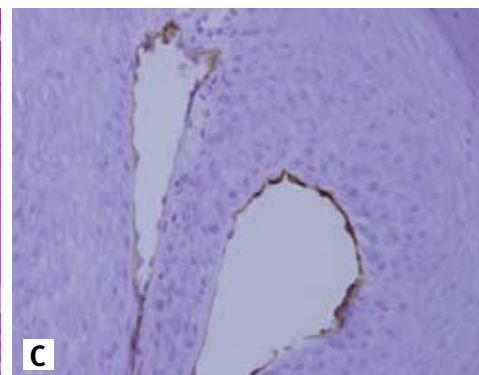
[A] Bilateral leg edema with verrucous thickening of the toes. The nails show dystrophy, thickening, yellow discoloration and overcurvature.



[B] A biopsy from edematous skin showing marked papillomatosis and acanthosis. There are dilated thin-walled vessels in the dermal papilla and upper dermis.



[C] The endothelial cells lining dilated vessels in a dermal papillae stain positively with D2-40 antibody.



endothelial cells were seen in the upper dermis along with mild perivascular mononuclear infiltrates [Figure B]. Some of the dilated vessels were partially encircled by the hyperplastic epidermis in the dermal papillae. Immunohistochemically, the endothelial cells stained positively with D2-40 antibody (Cell Marque, USA) [Figure C], and for VEGFR-3 (Millipore, Canada-USA), CD31 (Neomarkers, USA) and von Willebrand factor (Dako, Denmark).

COMMENT

Yellow nail syndrome (YNS, OMIM 153300) was first described in 1964 by Samman and White [1]. This rare syndrome is characterized by dystrophic, over-curved and slow-growing yellow nails, bilateral lymphedema of the legs, and lung abnormalities including pleural effusion and bronchiectasis. Other variable manifestations are recurrent sinusitis, recurrent respiratory tract infections, pericardial effusion and, rarely, ocular abnormalities. Yellow nail syndrome has been associated with autoimmune disorders such as thyroiditis, systemic lupus erythematosus and rheumatoid arthritis [5]. There are also isolated case reports of yellow nail syndrome associated with malignancy [5]. Familial cases have also been reported [5].

The pathogenesis of this syndrome has not been established. Some authors have proposed anatomic structural abnormalities of lymphatic vessels [1]. Abnormal lymphangiography has been demonstrated in patients with yellow nail syndrome [1], while others have

VEGFR-3 = vascular endothelial growth factor receptor-3

demonstrated abnormally functioning lymphatic vessels on lymphoscintigraphy analysis [1].

D2-40 is a novel monoclonal antibody that reacts with an epitope in lymphatic endothelium [2]. It is considered to be a sensitive and specific marker of lymphatic endothelium, since normal lymphatic endothelial cells stain positively for D2-40 while capillaries and small vascular vessels do not [2,4]. Pusztaszeri et al. [4] found that D2-40 stains small lymphatic vessels around bronchioles in the lungs. In addition, mesothelial cells from the pleura and bronchial wall chondrocytes are also occasionally positive. This was not found in other parenchymal organs [4].

Another novel marker for lymphatic endothelium that may be helpful in identifying endothelial cells of lymphatic malformation is VEGFR-3 [3]. CD31 is one of the best known markers for vascular endothelium [4]. In the skin, CD31 stains small arteries, arterioles, venules and capillaries [4]. Small parts of lymphatic vessels may express CD31 but only weakly and irregularly [4]. In our case, the dilated vessels stained strongly and uniformly for CD31. Similarly, von Willebrand factor, which is stored in endothelial cell-specific organelles known as Weibel-Palade bodies, is also considered a marker for vascular endothelium [4]. In the present case, the histopathological examination of skin from the edematous leg demonstrated dilated thin-walled vessels in the upper dermis. These vessels were stained positively with D2-40 antibody and with antibodies to VEGFR-3, CD31 and von Willebrand factor. A similarly combined vascular and lymphatic immunoreactivity was described previously in lymphangioma, Kaposi's sarcoma,

angiosarcoma and Dabska tumor [3]. Lymphatic anomalies occur concurrently with vascular malformation in both Klippel-Trenaunay syndrome and Parkes Weber syndrome [2]. The dual vascular and lymphatic endothelial differentiation, which is manifested in these tumors and malformations, may indicate abnormal vascular spaces that derive from a common immature precursor endothelial cell. This is consistent with previous reports suggesting that early development of lymphatic vessels is from veins and that both lymphatic and venous elements coexist in vascular malformations [2]. Therefore, the dual immunostaining pattern of the lymphedematous skin in our patient may reflect an underlying aberrant vascular development from a common precursor endothelial cell.

Corresponding author:

Dr. E. Avitan-Hersh

Dept. of Dermatology, Rambam Health Care Campus, Haifa 31096, Israel

Phone: (972-4) 854-2154

Fax: (972-4) 854-2951

email: e_avitan@rambam.health.gov.il

References

1. Bull RH, Fenton DA, Mortimer PS. Lymphatic function in yellow nail syndrome. *Br J Dermatol* 1996; 134: 307-12.
2. Galambos C, Nodit L. Identification of lymphatic endothelium in pediatric vascular tumors and malformations. *Pediatr Dev Pathol* 2005; 8: 181-9.
3. Folpe AL, Veikkola T, Valtola R. Vascular endothelial growth factor receptor-3 (VEGFR-3): a marker of vascular tumors with presumed lymphatic differentiation, including Kaposi's sarcoma, kaposiform and Dabska-type hemangiopericytomas, and a subset of angiosarcomas. *Mod Pathol* 2000; 13: 180-5.
4. Pusztaszeri MP, Seelentag W, Bosman FT. Immunohistochemical expression of endothelial markers CD31, CD34, Von Willebrand factor and Fli-1 in normal human tissues. *J Histochem Cytochem* 2006; 54: 385-95.
5. Gupta AK, Davies GM, Haberman HF. Yellow nail syndrome. *Cutis* 1986; 37: 371-4.

Religious freedom should work two ways: we should be free to practice the religion of our choice, but we must also be free from having someone else's religion practiced on us"

John Irving (born 1942), American novelist and Academy Award-winning screenwriter

"There comes a point when a man must refuse to answer to his leader if he is also to answer to his own conscience"

Hartley Shawcross (1902-2003), British barrister, politician, and prosecutor at the Nuremberg War Crimes tribunal