

# Thoracoscopic Azygos Vein Lobe Resection in a Patient with Synchronous Right and Left Lung Cancer

Michael Papiashvili MD<sup>1,5</sup>, Henri Hayat MD<sup>2</sup>, Letizia Schreiber MD<sup>3</sup> and Israel E. Priel MD<sup>4</sup>

Departments of <sup>1</sup>Cardiothoracic Surgery, <sup>2</sup>Oncology, <sup>3</sup>Pathology and <sup>4</sup>Pulmonary Medicine, Wolfson Medical Center, Holon, Israel

<sup>5</sup>Department of General Thoracic Surgery, Assaf Harofe Medical Center, Zerifin, Israel

All affiliated with Sackler Faculty of Medicine, Tel Aviv University, Tel Aviv, Israel

**KEY WORDS:** bilateral lung cancer, azygos vein lobe cancer, lung cancer surgery, thoracoscopy, lobectomy

IMAJ 2015; 17: 387–388

The azygos vein lobe, described by Wrisberg in 1877, is an anatomic variant due to an anomalous development of the right upper lobe and found in 0.1% to 8% of the population. Since the original description of carcinoma of the azygos vein lobe in 1969 by Mullin et al. [1], only a few cases have been reported in the literature [2,3], and only one on pulmonary adenocarcinoma originating in the azygos lobe [4]. The presence of synchronous bilateral lung carcinoma is another rare condition. Optimal treatment of synchronous lung carcinomas remains controversial due to difficulties in determining whether multiple lesions represent synchronous lung cancer or metastases. We present, to our knowledge, the first case of a 63 year old man after coronary artery bypass surgery, with synchronous primary adenocarcinoma of the azygos vein lobe and primary squamous cell carcinoma of the left upper lobe successfully treated surgically by bilateral staged thoracoscopy and thoracotomy techniques.

## PATIENT DESCRIPTION

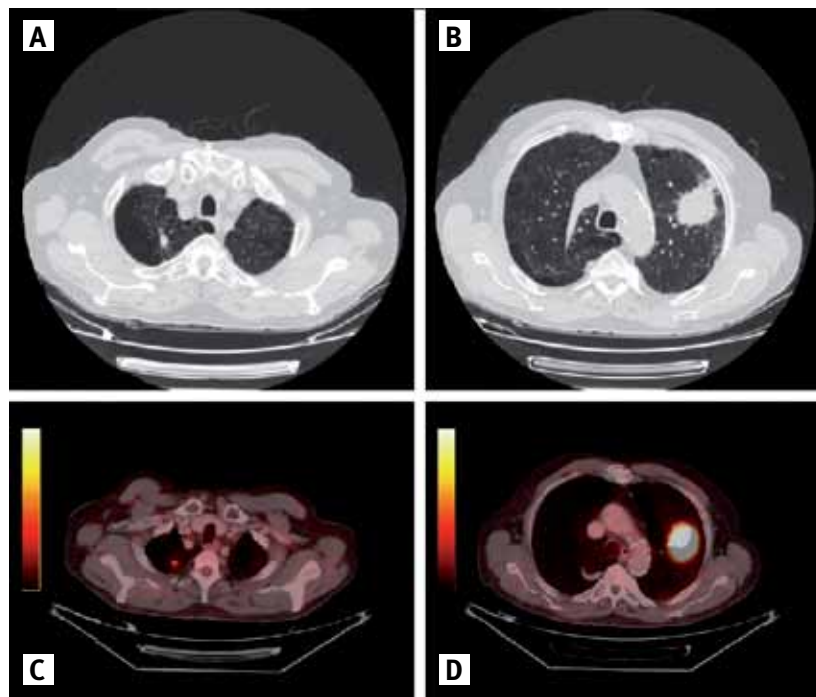
A 63 year old former smoker, post-coronary artery bypass surgery, with severe peripheral vascular disease, non-insulin-dependent diabetes mellitus, stubborn

Crohn's disease, and anxiety underwent routine chest radiography due to a common cold infection, which surprisingly showed a large left upper lobe mass and a small paratracheal lesion in the right upper lobe. A computed tomography scan of the chest and a positron emission tomography-computed tomography (PET-CT) scan revealed only a 60 x 55 mm solid positive central left upper lobe mass and a 13 mm spiculated positive nodule in the azygos vein lobe (which was separated by the thin fissure from the rest of the right upper lobe) [Figure 1]. Transthoracic nee-

dle biopsy of the left lung mass confirmed primary squamous cell lung carcinoma. Mean baseline FEV1% (forced expiratory volume in one second) of predicted (2.05 L and 66%, respectively) and ejection fraction (60%) were measured. Staged right azygos lobe resection and left upper lobe lobectomy was scheduled.

During the first operation, a 10 mm utility incision was made at the right mid-axillary line at the eighth intercostal space and a standard 10 mm degree thoracoscope was inserted through a 10 mm trocar (Tyco Healthcare, Tullamore, UK).

**Figure 1.** [A] CT scan showing an azygos vein lobe lesion. [B] CT scan showing a left upper lobe tumor. [C] PET-CT scan showing a positive nodule in the right azygos vein lobe. [D] PET-CT scan showing a positive mass in the left upper lobe



A second 10 mm utility incision was made at the right mid-clavicle line at the sixth intercostal space and a 2.5 cm working incision at the anterior axillary line at the fourth intercostal space just anterior to the latissimus dorsi muscle. Using endoscopic instruments, the mediastinal pleura between the superior vena cava and the trachea was opened above the azygos vein, which was gently removed from the mediastinum beneath the azygos vein and resected anatomically.

A 36 French straight chest tube was inserted through the 10 mm camera port incision and the other incisions were closed. The postoperative course was uneventful. On the fifth postoperative day the patient was discharged home in good general health.

Two weeks later, an anatomic left upper curative lobectomy with hilar and mediastinal lymph node dissection was performed through a standard serratus muscle-sparing posterolateral thoracotomy incision in the sixth intercostal space. During surgery the left upper lobe was scrupulously separated from the mediastinum by cautery due to severe adhesions after the coronary bypass grafting surgery, especially around the left internal mammary artery graft. Two 36 French chest tubes (one curved and one straight) were inserted and the chest was closed. The postoperative course was uneventful. On the eighth postoperative day the patient was discharged home in good general health.

Final pathology results from the bilateral lung cancer surgery diagnosed stage IA synchronous right lung adenocarcinoma

and stage IB synchronous left lung squamous cell carcinoma, without involvement of the hilar/mediastinal lymph nodes.

To date, more than 4 years after surgery, the patient is in good general health and free of disease.

---

### COMMENT

A second cancer may exist in the ipsilateral or contralateral lung at the time of primary lung cancer diagnosis. This second cancer may be a metastasis of the primary cancer, a metastasis from another organ, or a synchronous primary lung cancer. Multiple primary lung cancers diagnosed at the same time are called synchronous multiple primary lung cancers and are independent tumors of different histopathological type. With advances in diagnostic imaging, thoracic surgeons are increasingly encountering synchronous multiple primary lung cancer, which requires establishing the diagnosis of all lesions, especially if they are localized bilaterally.

Sequential delayed resection of synchronous multiple primary lung cancer lesions is the preferred treatment for such patients because it is safe and can be performed with acceptable morbidity and mortality rates ranging, according to recent study reports, from 1.1% to 8.5% [5].

Our case demonstrates a 63 year old patient with significant comorbidities diagnosed with left upper lobe primary squamous cell lung carcinoma positive on PET-CT and an additional contralateral lesion in the azygos lobe also positive on PET-CT, without mediastinal lymphadenopathy or distant metastasis.

The minimally invasive techniques used during the first surgery (thoracoscopic azygos vein lobe resection) preserved postoperative lung function as much as possible and helped the patient to completely recover and, after receiving final pathologic confirmation of the diagnosis of azygos vein lobe primary lung adenocarcinoma, prepare for the second surgery (left upper lobe lobectomy) for concurrent primary squamous cell carcinoma.

In conclusion, to the best of our knowledge, this is the first report of synchronous primary adenocarcinoma of the azygos vein lobe and primary squamous cell carcinoma of the left upper lobe successfully treated surgically by combined thoracoscopic and open approaches.

---

### Correspondence

**Dr. M. Papiashvili**

Dept. of General Thoracic Surgery, Assaf Harofe Medical Center, Zerifin 70300, Israel

**Phone:** (972-8) 977-9822

**Fax:** (972-8) 977-8149

**email:** michaelp@asaf.health.gov.il

---

### References

1. Mullin RL, Thomas DF, Baisch BF. Carcinoma of an azygos lobe. Report of a case. *J Thorac Cardiovasc Surg* 1969; 57: 839-40.
2. Mermet B, Blin D, Chandon JP, Dor V. Cancerized azygos lobe (apropos of an operated deceptive case). *Mars Med* 1971; 108: 708-10.
3. Sen S, Barutca S, Meydan N. Azygos lobe small cell carcinoma. *Eur J Cardiothorac Surg* 2004; 26: 1041.
4. Pinto CS, Santos N, Alves D, Cunha J, Miranda J, Vouga L. Therapeutic implication of the azygos vein lobe in patients with pulmonary adenocarcinoma. *Rev Port Cir Cardiotorac Vasc* 2009; 16: 207-10.
5. Voltolini L, Rapicetta C, Luzzi L, et al. Surgical treatment of synchronous multiple lung cancer located in a different lobe or lung: high survival in node-negative subgroup. *Eur J Cardiothorac Surg* 2010; 37: 1198-204.