



## Nutritional Rickets in Infants Immigrating to Israel from Ethiopia

Talia Ginat-Israeli MD, Zvi Dranitzki MD and Uri Straus MD

Maccabi Health Services Clinic, Mevasseret, Jerusalem, Israel

**Key words:** nutritional rickets, Ethiopian immigrants, vitamin D, sunlight

IMAJ 2003;5:291–292

For Editorial see page 289

Rickets is a metabolic bone disease characterized by failure of normal mineralization of the cartilage of growing bones, causing softening and weakening of the bones, leading to deformation and fractures. Rickets occurs primarily when the metabolites of vitamin D are deficient; however, recent reports from Nigeria suggest that calcium deficiency may be the major factor causing rickets in that country. Clinical manifestations of rickets include craniotabes, rosaries, thickening of the wrists, bowing of legs, and short stature. Extraskelatal manifestations include hypotony, tetany, convulsions and respiratory infections [1,2]. Nutritional rickets that was thought to have disappeared in developed countries has returned in recent years [3]. In the past 3 years, in a clinic in Mevasseret, a suburb of Jerusalem, we have treated a few infants with nutritional rickets, all new immigrants from Ethiopia. We present two of them.

### Patient Descriptions

#### Patient 1

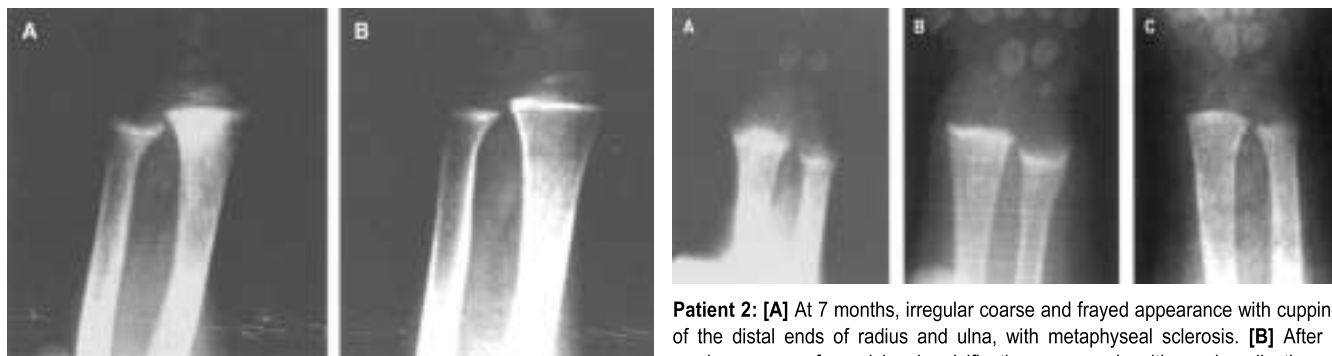
This patient was the sixth child born to his mother after a normal pregnancy and delivery. He emigrated from Ethiopia to Israel at the age of 13 months and was breast-fed until then. His psychomotor development was normal. Soon after arrival he was treated in the clinic for iron deficiency anemia (hemoglobin 7.5 g/dl); at that time no signs of rickets were observed.

At the age of 2 years he came to the clinic because of diarrhea. On examination he looked pale, weight 11.7 kg (27th percentile), height 80.5 cm (under the 5th percentile), head circumference 50 cm (88th percentile). There were rosaries and bowing of the legs (left more than the right); the teeth looked normal. Neurologic examination was normal. His diet consisted solely of a peanut snack ("Bamba") and artificial raspberry juice, and his mother reported that he refused any other food. Laboratory results revealed: calcium 8.9 mg/dl (normal 8.8–10.6), phosphorus

2.8 mg/dl (normal 3.5–5.6), alkaline phosphatase 657 u/L (normal 145–320), 25(OH)-vitamin D 7.8 ng/ml (normal 10–50), hemoglobin 9 g/dl, albumin 4.4 g/dl. Direct stool examination revealed *Giardia* in one of six samples; celiac serology was negative. X-ray of the wrist showed cupping and fraying of distal ulna and radius, with double lateral contour of the radius [Figure A]. A proper diet enriched with dairy products was recommended (containing at least 600 mg/day of calcium), and treatment with vitamin D 400 IU/day and elemental calcium 600 mg/day (and iron) was started. He was also encouraged to play outside in the sun. Compliance to diet was only partial, but 2 months after the beginning of therapy, blood tests normalized. X-ray after a few months showed improvement [Figure B].

#### Patient 2

This patient, the tenth child born to her mother after a normal pregnancy and delivery, came to the clinic at the age of 7



**Patient 1:** [A] At 2 years: cupping and fraying of the distal ends of radius and ulna. [B] At 2.5 years: calcification of the epiphyseal plate and metaphyses.

**Patient 2:** [A] At 7 months, irregular coarse and frayed appearance with cupping of the distal ends of radius and ulna, with metaphyseal sclerosis. [B] After 6 weeks, zones of provisional calcification appeared, with remineralization of metaphyses that grew toward the epiphyseal plate. There was still significant cupping of the ulna. [C] At 11 months, the rickets had healed.

months, a few days after emigrating from Ethiopia, because of common cold symptoms. Her mother did not nurse her and she was fed with boiled diluted cows' milk. She did not take any vitamins.

Examination revealed weight 5.700 kg (under the 5th percentile), height 60 cm (under the 5th percentile), head circumference 43.5 cm (65th percentile), and severe hypotony. Skeletal examination revealed a large anterior fontanel 5x7 cm, craniotabes, biparietal bossing, wrist widening and rosaries. Heart examination showed a systolic murmur, and palpation of the abdomen demonstrated hepatomegaly. Laboratory results were as follows: calcium 8.0 mg/dl (normal 8.8–10.6), phosphorus 4.5 mg/dl (normal 3.5–5.6), ALP 1,248 u/L (normal 145–320), 25(OH)vitamin D 10.8 ng/ml (normal 10–50), hemoglobin 9.6 g/L, albumin 4.2 g/dl. Wrist radiography showed cupping and fraying of radius and ulna with metaphyseal sclerosis and soft tissue swelling [Figure A]. Ultrasonic imaging of the brain and abdomen, and echo-Doppler of the heart were normal. Blood test results of the mother showed normal values of calcium, phosphorus, ALP, and vitamin D. The baby's diet was changed to standard formula containing calcium (400 mg/day) and vitamin D (300 IU/day), and she started treatment with vitamin D 480 IU/day, and iron. Compliance was quite good, she soon gained weight and her tonus became normal. After 6 weeks of treatment, ALP went down to 418 u/L (normal 145–320), and wrist X-ray showed improvement [Figure B]. After 5 months of treatment, ALP normalized, and wrist film showed healing [Figure C].

### Comment

Rickets was common among infants in urban areas until the early part of the 20th century, when the curative effects of

sunlight and oral vitamin D (such as cod liver oil) were observed. With routine supplementation of infants' diet with vitamin D, the disease virtually disappeared by the mid-20th century and remained a major medical problem only in developing countries and among immigrants from these countries [3]. The disappearance of rickets led to a controversy in the United States about the need for vitamin D supplementation in nursing infants. Recently however, there has been an apparent rise in the number of cases of nutritional rickets in the USA. Infants at risk are those who are breast-fed (human milk provides very little vitamin D), receive no oral supplementation, those with darkly pigmented skin that blocks the penetration of light, and those living in an inner-city area in the presence of smog [4]. Rickets may also be of concern in infants fed a strict vegetarian diet.

In Ethiopia, as in neighboring African countries, nutritional rickets is common and is associated with morbidity such as malnutrition and pneumonia. [5]. We report two infants, immigrants from Ethiopia to Israel, suffering from rickets. Rickets in these infants seems to have been caused by inappropriate diet, poor in both calcium and vitamin D. In patient 2, insufficient exposure to light, due to traditional clothing to give protection from the sun, might also be a factor; the other child (Patient 1) was old enough to play outside.

Many Ethiopian infants arrived in Israel during the last few decades. The mothers receive guidance for appropriate diet and vitamin supplementation of their babies, especially while weaning. There have been no reports of rickets among them until now. Since some of the manifestations of rickets are so severe and typical, one cannot presume that cases have been overlooked. A possible reason for the inappropriate diet in the infants reported here is poor social adaptation. The two babies are from single-parent families, with

many siblings. There may also be environmental factors in the specific area in Ethiopia from which they came that contributed to the rickets. Genetic factors might also play a role.

We treated these infants with vitamin D, calcium, sunlight and diet enriched with calcium. We gave less oral vitamin D than is usually recommended but added controlled exposure to sunlight with a close follow-up. This management proved to be efficient in both, as healing ensued.

We conclude that greater awareness to the possibility of rickets is needed. Caretakers and medical staff should carefully monitor the assimilation of proper diet and vitamin supplementation in Ethiopian immigrants to Israel. The most intensive follow-up should be of infants during their first year of life, and while weaning at any age.

**Acknowledgment.** We thank Chaya Berman BScRN, for her quality nursing intervention.

### References

1. Goiner TA, Foster C, Shope T. The many faces of Vitamin D deficiency rickets. *Pediatr Rev* 2000;21(9):296–302.
2. Thacher TD, Fischer PR, Pettifor JM, et al. A comparison of calcium, vitamin D, or both for nutritional rickets in Nigerian children. *N Engl J Med* 1999;341:563–8.
3. Tomashek KM, Nesby S, Scanlon KS, et al. Nutritional rickets in Georgia. *Pediatrics* 2001;107(4):45.
4. Kreiter SR, Schwatz RP, Kirkman HN, Charlton PA, Calikglu AS, Davenport ML. Nutritional rickets in African breast-fed infants. *J Pediatr* 2000;137:153–7.
5. Muhe L, Lulseged S, Mason KE, Simoes EAF. Case-control study of the role of nutritional rickets in the risk of developing pneumonia in Ethiopian children. *Lancet* 1997;349:1801–4.

**Correspondence:** Dr. T. Israeli, 29 Haoren Street, Mevasseret, Jerusalem 90805, Israel.  
Phone: (972-2) 533-3905  
Fax: (972-2) 570-0011  
email: taliaimd@netvision.net.il

ALP = alkaline phosphatase

*In the information age, you don't teach philosophy as they did after feudalism. You perform it. If Aristotle were alive today he'd have a talk show*

*Timothy Leary (1920-96), American psychologist, known as the 'guru of psychedelic utopias' for his advocacy of LSD*