

Left Subclavian Artery Occlusion by Thoracic Aortic Stent Graft: Long-Term Clinical and Duplex Follow-Up

Offer Galili MD¹, Simone Fajer MD¹, Avraham Eyal MD² and Ron Karmeli MD¹

Departments of ¹Vascular Surgery and ²Invasive Radiology, Carmel Medical Center, Haifa, Israel

Key words: thoracic aortic aneurysm, stent graft, subclavian artery coverage, subclavian steal syndrome, duplex

Abstract

Background: In recent years there has been an increase in endovascular repair of thoracic aortic aneurysms. In cases of insufficient neck length, occlusion of left subclavian artery achieves proper sealing and is usually well tolerated. Selected cases require revascularization of the left subclavian artery, including patients after coronary bypass surgery (left internal mammary to left anterior descending) and those with arm claudication or subclavian steal syndrome.

Objectives: To evaluate the tolerability of left subclavian artery occlusion by stent graft without revascularization.

Methods: Thirty patients with thoracic aortic aneurysms underwent endovascular repair between July 2000 and November 2004. Eleven of them had occlusion of the left subclavian artery that required revascularization in two. Follow-up (average 3 years) included: a) blood pressure measurements of both arms at rest, after effort and pulse palpation, and b) vertebral blood flow by duplex scan.

Results: Of nine patients with no revascularization, 8 (89%) tolerated left subclavian artery occlusion with no claudication or steal syndrome; one (11%) suffered mild claudication only after effort and required no intervention. No left radial pulses were palpated in the nine patients. Blood pressure measurements in the left arm showed an average decrease of 40%, which remained constant after induced effort in all patients and was clinically insignificant. Duplex scan demonstrated reverse flow in the left vertebral artery in 8 of 9 patients (89%) and occlusion in 1 (originating in the arch and covered by the stent graft) with no clinical symptoms.

Conclusions: Left subclavian artery occlusion by stent graft is a tolerable procedure in the long term. In most cases, the constant decrease in blood pressure remained unchanged during follow-up and had no significant adverse affects. Most patients do not require revascularization prior to the endovascular procedure.

IMAJ 2007;9:668–670

The treatment of thoracic aortic diseases has expanded with the advanced development of endovascular systems. Endoluminal deployment of stent grafts requires a sufficient “neck,” defined as a normal aortic segment of at least 1.5–2 cm, to allow for proper anchoring and sealing [1,2]. This requirement is problematic in cases of thoracic aortic aneurysms with a short neck distal to left subclavian artery, especially in cases of post-traumatic TAA. To create an adequate neck, occlusion of the left subclavian artery is performed by covering its orifice. In extreme cases, the left common carotid artery can be covered after performing right-to-left common carotid bypass. As a result of left subclavian artery

occlusion, collateral supply to the arm results from several arteries: vertebral (reverse flow), left internal mammary and the thyrocervical trunk. Occlusion of the left subclavian artery may result in several possible complications: subclavian steal syndrome, claudication of the left arm, and cardiac ischemia/unstable angina in patients after coronary bypass (LIMA to LAD).

Several authors have favored revascularization procedures prior to endovascular treatment to avoid these complications [2-5]. Other reports described intentional left subclavian occlusion by stent grafts without revascularization as a tolerable procedure [6-12]. We report a series of 11 patients in whom the orifice of the left subclavian artery was intentionally covered during endoluminal deployment of a thoracic stent graft.

Patients and Methods

The study population comprised 30 patients with TAA, treated endovascularly between July 2000 and November 2004. Occlusion of the left subclavian artery was performed in 11 patients (9 males and 2 females – the study group) [Figures 1 and 2]. All patients gave their informed consent after receiving a detailed explanation. In one case, the left vertebral artery originated directly from the aorta and was also occluded. Two types of endoprostheses were used: “Excluder” thoracic endoprosthesis (W.L. Gore & Associates Inc., Flagstaff, Arizona USA) in four patients, and “Talent” (Medtronic, Minneapolis, USA) in the other seven. The mean diameter of the aneurysms was 60 mm. Among the TAAs, three were post-traumatic aneurysms. One patient was operated in an emergency procedure due to acute traumatic rupture of the thoracic aorta.

Most procedures were performed under general anesthesia, and stents were introduced through a femoral approach. One patient had a prior left carotid to left subclavian artery bypass, from previous cardiac bypass artery bypass surgery using both right and left intimal mammary arteries. A second case had coverage of the left common carotid artery and therefore underwent right-to-left common carotid artery bypass as well as right-to-left subclavian bypass. The remaining patients did not undergo revascularization of the left subclavian artery. Follow-up included a computed tomography angiography 3 days, 3 months and yearly thereafter. CTA was used to diagnose failure of stent

LIMA = left internal mammary

LAD = left anterior descending

CTA = CT angiography

TAA = thoracic aortic aneurysm

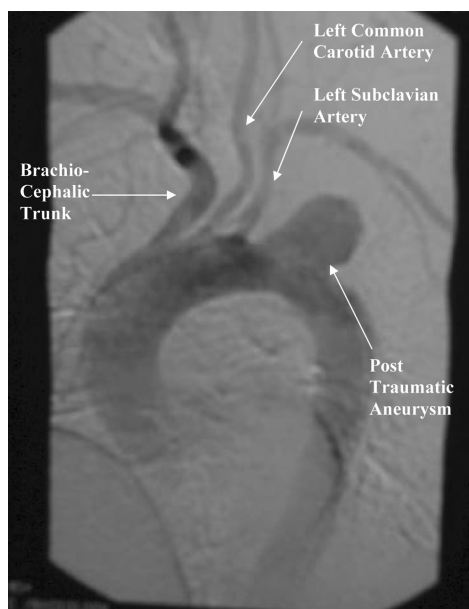


Figure 1. Post-traumatic thoracic aortic aneurysm. The aneurysm is located at the aortic isthmus with a “neck” of less than 1 cm from the orifice of the left subclavian artery.

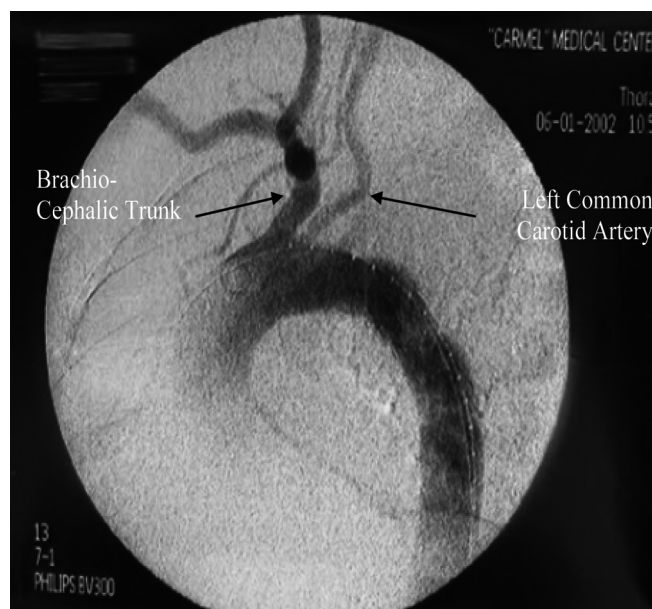

Figure 2. Completion angiography after endovascular treatment. The orifice of the left subclavian artery was covered and occluded by the stent graft.

graft deployment as well as late complications such as endoleaks and dislocations. In addition, follow-up (average \pm SD 32 \pm 15 months) included blood pressure measurements of both arms at rest, after effort (repetitive arm lifting) [13] and pulse palpation, and vertebral artery blood flow by duplex (direction and velocity).

Results

The use of stent grafts was successful in all patients, as confirmed by aortography during the procedure. CTA performed 3 days after the procedure demonstrated the correct position of the stent grafts and the absence of leaks. One patient had a minor stroke (most probably embolic) during the procedure which resolved completely, and one patient had mild reversible pulmonary complications. No major complications were recorded during the 30 day postoperative period. Of the 11 patients with no revascularization 9 tolerated left subclavian occlusion with no claudication or steal. One of these nine suffered mild effort claudication and required no intervention. No left radial pulses were palpated in these nine patients. Systolic blood pressure measurements in the left arm showed an average 40% decrease and remained unchanged during follow-up. There was also no change in vertebral blood flow by duplex. This decrease in blood pressure remained constant after induced effort in all patients and was clinically insignificant. Duplex scan demonstrated reverse flow in the left vertebral artery in eight of the nine patients and occlusion in one patient with no clinical symptoms [Table 1].

Discussion

Treatment of thoracic aortic disease with endovascular stent graft systems is feasible and carries a lower rate of morbidity and mortality compared to open surgery [14]. One of the limitations of the endovascular procedure includes the need for a sufficiently long proximal aneurysm “neck” [1,2]. In TAAs of a post-traumatic nature, the aneurysm usually begins at the aortic isthmus close to the orifice of the left subclavian artery. In these cases, proper anchoring and sealing of the stent graft includes covering the orifice of the left subclavian artery. In an early report by Ehrlich and colleagues [3], revascularization of the left subclavian artery prior to insertion of the stent graft was favored. However, the intentional occlusion of the left subclavian artery by stent graft

Table 1. Follow-up: symptoms and measurements (taken at the last follow-up visit)

Patient no.	Radial pulse Rt/Lt	Dizziness (present or not during effort)	Lt. arm claudication	Systolic BP Rt/Lt (mmHg)	Effort systolic BP Lt. arm (mmHg)	Duplex vertebral artery Rt/Lt (cm/sec)	Duplex flow direction in the vertebral artery Rt/Lt	Follow-up period (months)
1	+/	+	+	170/120	118	95/63	Ant/reversed	48
2	+/-	-	-	197/107	110	107/75	Ant/reversed	24
3	+/-	+/-	-	139/80	75	60/40	Ant/reversed	48
4	+/-	-	-	165/95	95	46/210	Ant/reversed	48
5	+/-	-	-	169/111	110	210/109	Ant/reversed	24
6	+/-	-	-	130/90	90	60/70	Ant/reversed	24
7	+/-	-	-	131/80	73	150/70	Ant/reversed	12
8	+/-	-	-	120/80	80	90/60	Ant/reversed	24
9	+/-	-	-	123/68	70	60/0	Ant/occluded	36
10*	+/+	-	-	138/127	130	70/0	Ant/occluded	48
11*	+/+	-	-	164/160	160	81/62	Ant/ant	12

* Revascularization of left subclavian artery prior to endovascular procedure

without prior revascularization has been reported [6,8-12], with a low incidence (0–15%) of left arm symptoms – both acute and during follow-up [8,10-12].

According to our experience most patients are asymptomatic after left subclavian artery occlusion, irrespective of vertebral artery flow. Only one case with a previous CABG and LIMA to LAD needed a procedure to prevent cardiac ischemia. Duplex scans of the left vertebral artery were performed in all our patients [Table 1]. Collaterals (aside from the vertebral artery) from the LIMA and thyrocervical branches apparently supplied sufficient flow to the left subclavian artery. This is especially evident in cases of left vertebral occlusion. Interestingly, although eight patients demonstrated reverse flow in the left vertebral artery, none of them suffered any neurological sequelae (subclavian steal syndrome). The absence of neurological symptoms most probably indicates patent intracerebral communicating arteries in the brain. These results may imply that four-vessel angiography is not necessary before left subclavian occlusion. With increasing experience in non-invasive imaging (CTA) versus invasive imaging (four-vessel angiography), a CTA with or without duplex may be sufficient.

The current study confirms that occlusion of the left subclavian artery orifice with a stent graft is well tolerated. In most cases the constant decrease in blood pressure remained unchanged during a long follow-up and had no significant clinical adverse affects. The decision for revascularization can be made post-procedurally if left arm claudication or subclavian steal symptoms develop. The current data add to the accumulating literature supporting preventive revascularization prior to endovascular repair of TAA only in cases with a prior LIMA to LAD bypass.

References

1. Dake MD. Endovascular stent-graft management of thoracic disease. *Eur J Radiol* 2001;39:42–9.
2. Fann JJ, Miller DC. Endovascular treatment of descending thoracic aortic aneurysms dissections. *Surg Clin North Am* 1999;79:551–74.
3. Ehrlich M, Grabenwoeger M, Cartes-Zumelzu F, et al. Endovas-

cular stent graft repair for aneurysms on the descending thoracic aorta. *Ann Thorac Surg* 1998;66:19–25.

4. Heijmen RH, Deblieer IG, Moll FL, et al. Endovascular stent-grafting for descending thoracic aortic aneurysm. *Eur J Cardiothorac Surg* 2002;21:5–9.
5. Bortone AS, Schena S, Mannatrzio G, et al. Endovascular stent graft treatment for diseases of the descending thoracic aorta. *Eur J Cardiothorac Surg* 2001;20:514–19.
6. Hausegger KA, Oberwalder P, Tiesenhausen K, et al. Intentional left subclavian artery occlusion by thoracic aortic stent-grafts without surgical transposition. *J Endovasc Ther* 2001;8:472–6.
7. Mattison R, Hamilton IN, Ciraulo DL, Richart CM. Stent-graft repair of acute traumatic thoracic aortic transection with intentional occlusion of the left subclavian artery: case report. *J Trauma* 2001;51:326–8.
8. Tiesenhausen K, Hausegger KA, Oberwalder P, et al. Left subclavian artery management in endovascular repair of thoracic aortic aneurysms and aortic dissections. *J Cardiac Surg* 2003;18:429–35.
9. Matravers P, Morgan R, Belli A. The use of stent grafts for the treatment of aneurysms and dissections of the thoracic aorta: a single centre experience. *Eur J Vasc Endovasc Surg* 2003;26:587–95.
10. Riesenman PJ, Farber MA, Mendes RR, Marston WA, Fulton JJ, Keagy BA. Coverage of the left subclavian artery during thoracic endovascular aortic repair. *J Vasc Surg* 2007;45:90–4; discussion 94–5.
11. Caronno R, Piffaretti G, Tozzi M, Lomazzi C, Rivolta N, Castelli P. Intentional coverage of the left subclavian artery during endovascular stent graft repair for thoracic aortic disease. *Surg Endosc* 2006;20:915–18.
12. Schoder M, Grabenwoeger M, Holzenbein T, et al. Endovascular repair of the thoracic aorta necessitating anchoring of the stent graft across the arch vessels. *J Thorac Cardiovasc Surg* 2006;131:380–7.
13. Sharp MA, Harman E, Vogel JA, Knapik JJ, Legg SJ. Maximal aerobic capacity for repetitive lifting: comparison with three standard exercise testing modes. *Eur J Appl Physiol* 1988;57:753–60.
14. Coselli JS, LeMaire SA, Miller CC. Mortality and paraplegia after thoracoabdominal aneurysm repair: a risk factor analysis. *Ann Thorac Surg* 2000;69:409–14.

Correspondence: Dr. R. Karmeli, Chairman, Dept. of Vascular Surgery, Carmel Medical Center, Haifa 34362, Israel.

Phone: (972-4) 825-0267

Fax: (972-4) 825-0898

email: carmeli_ron@clalit.org.il